

## CASE REPORT

# Necrosis of the Brain in Calves Following Dehorning

P. N. NATION AND W. A. CALDER

*Animal Health Laboratory, Alberta Agriculture, P.O. Bag 1, Airdrie, Alberta T0M 0B0 (Nation) and Okotoks Animal Clinic, Box 368, Okotoks, Alberta T0L 1T0 (Calder)*

### Abstract

This is a report of an acute hemorrhagic necrotizing encephalitis following dehorning in calves on pasture. Calves were found either dead or down in extremis. Multiple necrotic inflammatory lesions were found in the cerebral cortices of affected calves at postmortem. Necrosis and hemorrhage were observed microscopically to be more prominent than inflammation, indicating the peracute overwhelming nature of the process. The etiology was not determined but clostridial infection was suspected.

**Key words:** Brain, encephalitis, calves.

### Résumé

#### Nécrose cérébrale consécutive au décornage, chez des veaux

Cet article rapporte une encéphalite aiguë, hémorragique et nécrotique, consécutive au décornage de veaux en paissance. Le propriétaire les trouva morts ou moribonds. La nécropsie de ces veaux révéla la présence de plusieurs lésions inflammatoires et nécrotiques, dans le cortex cérébral. L'histopathologie démontra que la nécrose et l'hémorragie prédominaient sur l'inflammation, indice de l'allure suraiguë de la condition. On soupçonna la possibilité d'une infection à clostridies, même s'il s'avéra impossible de la démontrer.

**Mots clés:** cerveau, encéphalite, veaux.

### Introduction

Complications from dehorning cattle are observed occasionally by clinicians but are not reported often in the veterinary literature. The most common complications are excessive hemorrhage or frontal sinusitis in older cattle (1) and skin burns due to overexuberant application of caustic dehorning paste in younger animals. The first two complications relate to the larger vessel size and the larger volume of the frontal sinuses of older cattle.

The following is a report of an outbreak of hemorrhagic necrotizing encephalitis associated with dehorning wounds in a number of calves on a southern Alberta ranch.

### History and Clinical Findings

Late in May a range herd of 200 cows with two to four week old calves at foot was assembled. All calves were dehorned with a gouge and were wattled using a knife. Attempts were made to perform dehorning and wattling<sup>1</sup> operations as cleanly as possible, however equipment was not disinfected between calves. The herd was released to summer range on a section of land on the east slope area of the Rocky Mountain foothills west of Calgary. Four days later, the owner found four dead calves. The following day, five more calves were found either dead or recumbent. Downer calves were found in lateral recumbency and in respiratory distress and all died within a few hours of being found.

Seven dead calves were presented to the Alberta Agriculture Airdrie Veterinary Laboratory for postmortem examination.

### Postmortem and Laboratory Findings

Significant pathological findings were restricted to the structures of the head and the brain in all animals examined. All calves were in good body condition and had bilateral deep circular gouges in the skin of the poll region of the head at the site of removal of the germinal corium of the horns. These gouges extended through the periosteum into the outer cortex of the frontal bone. All calves had a wattling cut in the skin of the right cheek. Connective tissues of the head were edematous. Edema was especially prominent over the frontal bones and around the eyes and was particularly severe in three calves.

All calves had discoloured areas of necrosis and hemorrhage in the cerebral cortices (Figure 1). Necrotic areas were red-brown, relatively uniform in size, irregularly spherical, measured up to 1 cm in diameter and were restricted to the grey and white matter of the superficial regions of the cerebral hemispheres. The central regions of these lesions were completely necrotic whereas the edges blended gradually into the surrounding neuropil.

One calf had a distinct grey discoloration of the right occipital bone with hemorrhage. This lesion was located between a dehorning wound on the outer surface and discolored areas of

Present address of Dr. Nation: Department of Pharmacology, Faculty of Medicine, University of Calgary, 3330 Hospital Drive N.W., Calgary, Alberta T2N 4N1.

<sup>1</sup>"Wattling" is a procedure uncommonly employed by some ranchers in range areas of western North America as an aid in identification of calves. An incision is made in the skin of the cheek or the dewlap in such a way that a flap is created.

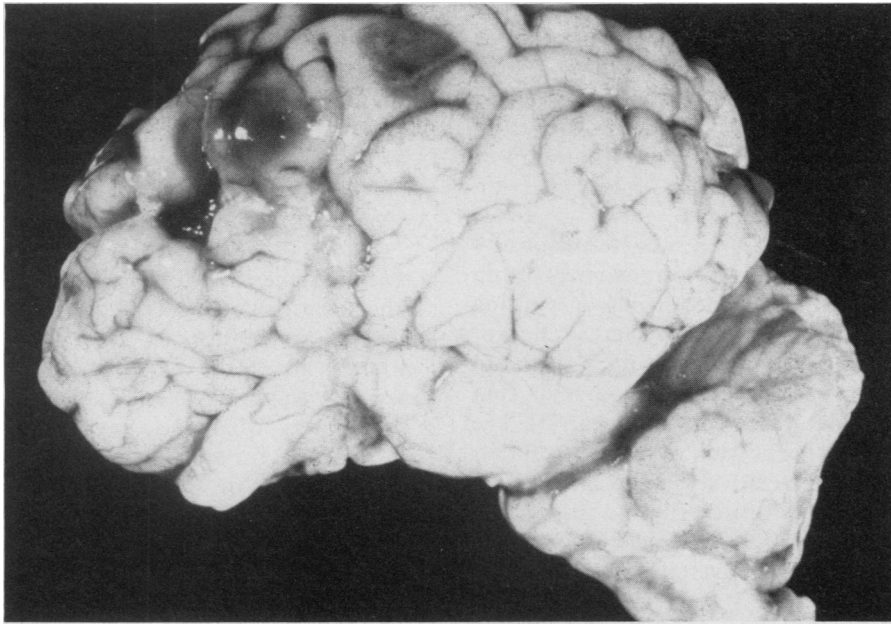


FIGURE 1. Discolored areas of necrosis and hemorrhage in the cerebral cortex and meningeal edema of the brain of a calf.

necrosis and hemorrhage in the adjacent cerebral cortex.

Samples of affected areas of brain were taken for aerobic and anaerobic bacterial cultures, fungal cultures and fluorescent antibody (FAT) examinations for *Clostridium novyii*, *chauvei* and *septicum*. Other samples of brain were removed and fixed in 10% neutral buffered formalin, processed routinely, embedded in paraffin and sectioned at 6 microns. Sections were stained with hematoxylin and eosin (H&E) and Brown and Brenn (B&B) stains.

Microscopic examination of the brains revealed necrosis and hemorrhage with varying degrees of inflammation throughout all discolored areas noted grossly. The most dramatic inflammatory lesions consisted of severe suppurative meningitis with marked thickening of the meninges and filling of the meningeal spaces with neutrophils. There was some fibrin exudation into the meninges and the meninges were edematous. The neutrophil reaction extended from the meninges into the underlying grey matter of the brain. Neutrophils and small numbers of mononuclear cells had emigrated from veins in affected areas into the surrounding neuropil. Most inflammatory cells had under-

gone necrosis within a few microns of the vascular wall. The number of inflammatory cells in the foci of necrosis varied considerably from area to area. In some foci there were very few cells while in others there were large numbers emigrating from veins as described. The inflammatory reaction was confined primarily to the edges of the necrotic zones and suggested that necrosis had occurred initially and inflammation secondarily as a terminal event in previously existing areas of inflammation.

Bacteria were not seen either on H&E or B&B stained sections.

All cultures were negative for significant bacteria and fungi. Negative results were obtained by FAT for *Clostridium novyii*, *chauvei* and *septicum*.

Following the gross postmortem examination a tentative diagnosis of clostridial infection was made. The owner again assembled all calves and gave each one a dose of 8-way vaccine (Covexin 8, Burroughs Wellcome Inc., Kirkland, Quebec) and a single injection of long-acting penicillin (Pendure Neat, Armitage Carroll Ltd., London, Ontario) consisting of 150,000 IU benzathine penicillin G and 150,000 IU procaine penicillin G per mL. Four calves escaped and were not treated.

No further losses occurred for ten days but following this one additional calf was found dead and a second calf was found recumbent. Severe swelling was present in the connective tissues of the head. The calf was treated with 4.5 million IU procaine penicillin (Pen-Aqueous, Armitage Carroll Ltd., London, Ontario), but died within twelve hours. Neither calf was subjected to postmortem examination.

#### Discussion

Hemorrhagic lesions of the bovine brain accompanied by neutrophil response are seen most commonly in Alberta as a result of *Haemophilus somnus* septicemia. Commonly described as infarcts, the lesions of *H. somnus* infection are actually multifocal areas of suppurative vasculitis, vascular thrombosis, encephalitis and necrosis randomly distributed throughout the brain.

The lesions described in this report were much larger and more necrotic than those normally produced by *H. somnus*. Furthermore, they were restricted to the cerebral cortex and the inflammatory response was located primarily in the periphery of the lesion, in contrast to those associated with *H. somnus*. The distribution of the brain lesions and lack of lesions elsewhere in affected calves suggested that they arose by direct extension through the bones of the cranial vault. In support of this idea was the finding in one calf of discolored necrotic bone interposed between and in direct contact with brain lesions on one side and a dehorning wound on the other.

The veins of the brain are valveless and very thin walled, having no smooth muscle. They anastomose freely, especially on the surface of the brain (2). Similarly, the cranial venous sinuses into which cranial veins drain are valveless. It is known that the ventral venous sinuses of the brain can be invaded by bacteria entering veins of such cranial structures as the nasal cavity, orbit and upper teeth (2). In the present case the periosteum and outer layers of the frontal bones underlying the dehorning wounds were damaged. Any bacteria that may have been carried to this site by the dehorning gouge could have entered vessels of the occipital bones. From here they would have had only a short distance to traverse

before invading the veins of the meninges and the superficial veins of the cerebral hemispheres from whence, due to the lack of valves and multiple anastomoses, they could establish infection anywhere in the cerebral hemispheres. In fact, this hypothesis is supported by the distribution of observed lesions, which appeared only in areas drained by the dorsal venous sinuses of the brain.

The lesions in these calves were not associated with a specific microbiological agent. In this circumstance, trauma to the cranium caused by the dehorning gouge might logically be expected to be the etiology of the lesions described. Despite this, a number of factors suggested that clostridial infection of the dehorning wounds might have been responsible for the observed lesions. The clinical onset of disease began four days after dehorning and wattling and all but two deaths occurred during a period of 48 hours. There was edema of the head in all calves examined at postmortem and the lesions in the brains were primarily necrotic and hemorrhagic, a common observation in clostridial infections. With two exceptions, death losses stopped following penicillin

treatment and vaccination of the calves, suggesting the possibility of response to penicillin therapy.

For these circumstantial reasons and despite the negative FAT and B&B stain results the authors are of the opinion that clostridial infection cannot be excluded.

The authors are not aware of any reports of similar lesions of the brain associated with dehorning or wattling in cattle. There is, however, a report of a somewhat similar lesion in the brain of two four week old goat kids that were dehorned with a hot iron (3). The lesions in the kids were single, unilateral and relatively much larger than those we observed in the calves reported upon here. The lesions were attributed to "overenthusiastic" use of the hot iron (3).

The lesions that we observed were multiple in all calves, involved both cerebral hemispheres and were reasonably uniform in size, measuring no more than 1 cm diameter. The gross appearance of affected regions of brain and the type of inflammatory reaction seen microscopically in these calves was similar to that described in goat kids (3).

In conclusion, we herein describe a

lesion arising as a complication of dehorning and wattling which consists of necrosis and inflammation of the brain and which we suggest might be due to clostridial infection of affected calves.

#### *Acknowledgments*

The authors would like to acknowledge the assistance of Dr. Peter Flood, Head of the Department of Veterinary Anatomy, Western College of Veterinary Medicine, Saskatoon, Saskatchewan for assistance with reference materials on the vascular anatomy of the bovine head.

#### *References*

1. JUBB KV, KENNEDY PC. Pathology of domestic animals. 2nd ed. New York: Academic Press, 1970.
2. KING AS. A guide to the physiological and clinical anatomy of the central nervous system. 6th ed. Published by the author. Department of Veterinary Anatomy, University of Liverpool, England, 1978.
3. DICKSON J. Brain damage in dehorned goat kids. *Vet Rec* 1984; 114: 387.

## **APPLICATIONS ARE INVITED FOR THE CANADIAN VETERINARY RESEARCH FELLOWSHIP**

This fellowship is funded by The Canadian Veterinary Research Trust Fund. Deadline for applications is February 20, 1986. More detailed information is provided in the yellow pages of this issue.

For further information and application forms, contact:

The Manager  
Canadian Veterinary Research Trust Fund  
339 Booth Street  
Ottawa, Ontario  
K1R 7K1  
Telephone: (613) 236-1162