

CHAPTER 15

METHODS OF CLOSED FIXATION

DAVID M. NUNAMAHER

◀ Prev Next ▶ Home Contents Glossary

- [Emergency Management of Fractures](#)
- [Ehmer Sling](#)
- [VelpEAU Sling](#)
- [Robert Jones Dressing](#)
- [Cranial Half Casts](#)
- [Functional Below the Knee Cast](#)
- [Schroeder-Thomas Splint](#)
- [Casting](#)

The use of closed methods of immobilization of fractures and dislocations has a long history in veterinary orthopaedics(1,2,4). The problems associated with this form of treatment have led to the development of other methods such as internal fixation. Although recently most of the veterinary orthopaedic literature has dealt with methods of internal fixation, a great majority of fractures in small animals are still treated successfully and sometimes optimally with external fixation methods, including casts, splints, slings, and wraps. The purpose of this chapter is to provide the reader with a correct method for applying casts, splints, and other methods of closed fixation that have proved successful over the years in treating injuries for which they are indicated. Some methods of external immobilization that may be used regionally are not included; their exclusion is not meant to signify inadequacies with those methods but simply my lack of experience with them.

EMERGENCY MANAGEMENT OF FRACTURES

One of the most widely repeated maxims of emergency care is "Splint them where they lie." The use of a splint to prevent further damage to soft tissue as well as to prevent the possibility of open fracture demands correct emergency splinting procedures. The casts and splints that are described in this chapter can be used in emergency treatment for immobilization, as a temporary measure for transportation, and as immobilization in the hospital prior to and including definitive fracture treatment. The problem with emergency splinting is related to the quality of the procedure. When a splint is applied to an extremity it is very important that it immobilize the part of the extremity for which it is intended. All too often emergency splints are used in such a way that the splint or immobilizing qualities of the splint end at or near the fracture. This can be more detrimental to the animal than would be the absence of splinting altogether. Once an animal is properly splinted, greater freedom can be allowed in his general movement and transport than with an animal that has no splint. If, however, the splint is improperly applied, more severe damage may be done to muscles, nerves, blood vessels, or the integument. Therefore, it is important to use temporary emergency splinting to adequately immobilize the injured part. The materials for emergency splinting may be those used in definitive fracture treatment or may be those that are available at the scene of the injury. Many injured animals can successfully guard their injuries and if handled adequately on a board or stretcher can be transported without the use of casts or splints. Some very distal injuries, however, will require emergency splinting to prevent closed fractures from becoming open while awaiting definitive treatment. Although experience will temper the course of action, emergency splinting should be used whenever it can adequately immobilize the injured part.

TAPPING THE FOOT

Attachment of the limb to the cast or splint is usually accomplished by the use of a distal stirrup made of tape. It is very important in the dog that this stirrup be applied to the dorsal and volar surface of the foot (Fig. 15-1). No lateral or encircling bands should ever be used when applying a stirrup to a dog's foot. Their use to ensure holding of the foot may cause irreparable damage in the form of vascular compromise. Sloughing of toes and other soft tissue injuries associated with casts and splints are reprehensible. If trouble is encountered in attaching the stirrup to the foot, a solvent such as ether should be used to adequately dry and degrease the foot so that the tape will stick. Although used for many years, padding of toes with cotton is probably not necessary. If too much cotton is used, an additional compromise of vascularity can occur, even when tape is applied in an accepted manner.



FIG 15-1 Application of a foot stirrup is shown on the dorsal and volar surface of the paw.

PADDING

Applying padding to a cast or brace may increase patient wearability, but it may also decrease the immobilization of the part. It is therefore important to understand for what reason a cast or splint has been applied so that an adequate but minimal amount of padding will be used. It may not be necessary to pad an animal's leg at all if, in fact, the hair is still present. The incorporation of plaster with the hair will provide an adequate boundary with the skin that will prevent the motion

between the skin and the cast that causes chafing pressure sores. Judicious use of padding will be advantageous in cases in which the skin has been prepped for surgery and there is no hair present on the leg. Usually two layers of cast padding are adequate and are accomplished by applying the padding in an overlapping manner so that each roll is overlapped one half, thus providing the two layers. For many years it has been theorized and practiced in both human and veterinary orthopaedics that to properly immobilize a limb the joints above and below the fracture site need also to be immobilized. This criterion of external cast fixation has been successfully challenged in human orthopaedics by Sarmiento with the use of his functional below-the-knee cast-brace system in fractures of the tibia, radius and ulna. Cast bracing has been applied to the femur as well. The same criteria that apply to humans seem also to apply to animals, and I have successfully used the Sarmiento-type below-the-knee cast for tibial fractures for the past 5 years. It would appear that if proper immobilization is used it is not always necessary to immobilize the joint above or below the fracture. The skill of the orthotist and the experience of the surgeon will determine where and when it is necessary. Opinions in regard to external fixation as well as internal fixation vary greatly; this chapter is intended to provide a description of external casting and splinting techniques that I have found to be successful.

EHMER SLING

The Ehmer sling was introduced into veterinary medicine to stabilize reduced anterior dorsal coxofemoral luxations in the dog and cat. The sling has the advantage that it does not immobilize the hip joint but places the femoral head into a position within the acetabulum in which it is most stable. In this way the animal can flex and extend the coxofemoral joint, which may be advantageous for rehabilitation.

INDICATIONS

The primary indication for the Ehmer sling is to provide stability following reduction of a cranial and dorsal dislocation of the hip joint. The basic purpose of the sling is to provide abduction and internal rotation of the femur and flexion of the knee, thereby shortening the lever arm of the hip joint and increasing the contact area of this ball and socket joint. The Ehmer sling is not useful with ventral dislocation of the hip, since abduction of the leg would be contraindicated and may cause relaxation.

APPLICATION

The Ehmer sling is a figure-of-eight dressing that is usually applied first with an elastic gauze such as Kling and then covered with tape. The figure-of-eight motion may be started in either the right- or left-hand direction ([Fig.15-2](#)). Description here will be in a clockwise direction using the left hind leg. Beginning on the plantar lateral aspect of the hind paw the gauze roll is unrolled so that it progresses up the medial aspect of the thigh and over the quadriceps musculature. The leg is flexed and the bandage roll is continued laterally over the thigh and medial to the hock joint. The bandage then comes to overlap the paw and the process is repeated two or three times. It is often helpful to allow the elastic gauze to go over the claws of the foot, thereby providing an anchorage of the bandage on the foot. Following application of the elastic gauze dressing, 1- or 2-inch tape is used over the gauze to provide strength and durability. It is important that no bandage material be wrapped circumferentially around the foot, since it may cause swelling or necrosis. Additional abduction of the limb may be accomplished by attaching tape to the foot and wrapping it around the body in a barber pole-type of configuration. This additional abduction is sometimes needed if relaxation seems probable. When completed, the Ehmer sling should shorten the leg by flexing the knee and hock, internally rotate the femoral head deeply within the acetabulum by externally rotating the hock joint, and abduct the leg. If the barber pole configuration is used for additional abduction, it is important that the tape not contact itself on the body wall of the dog, since this can cause severe skin abrasions within a week's time. Following application of the sling, the limb should be gently tested for stability, and postmanipulation radiographs should be made to confirm the reduction. The sling is usually left in place for a 10-day period. Additional time may be necessary in some cases, but prolonged use of the Ehmer sling may result in flexure contractures of the knee, and hock with a prolonged rehabilitation time. It is important that the bandage be checked periodically to make sure that there are no abrasions of the skin and that the tape is not cutting through the skin in any part of the leg. Following application of the Ehmer sling, animals are strictly confined for 10 days. Following removal of the sling, the foot will usually touch the ground within 24 hours and weight bearing will begin gradually over the next 3 days. Ten days is not sufficient time to have gained full stability of the hip joint, and further confinement and exercise on a leash are recommended for an additional 2 to 3 weeks.



FIG. 15-2 An Ehmer sling is shown in place.

VELPEAU SLING

The Velpeau sling is a shoulder bandage that will relieve the forelimb of weight bearing. It keeps the carpus, elbow, and shoulder joints in a flexed position.

INDICATIONS

The sling can be used for immobilization of scapular fractures, dislocations of the shoulder joint following reduction if stable in flexion, as well as for any indication for the removal of weight bearing from a foreleg. The animal seems to be comfortable with the sling, which can usually be left in place for approximately 10 days.

APPLICATION

The Velpeau sling is applied using a long piece of combine roll. The roll should be long enough to go around the animal's thorax approximately 3 1/2 times. The bandage is started by applying the combine roll around the dorsal surface of the

dog's radius and ulna. The combine roll makes one revolution around the radius and then moves up over the shoulder and around the thorax (Fig. 15-3, A) behind the opposite front leg, around to cover the flexed carpus, over the shoulder, around the thorax once more, behind the elbow joint, over the shoulder in front of the opposite forelimb and around the chest, again in front of the carpus. The sling is then taped to the body wall in a way that prevents the elbow from coming out posteriorly and the forepaw from coming out anteriorly (Fig. 15-3, B). Following application of the dressing it can be left in place for approximately 10 days. At that time it usually must be changed because of loosening. The device is rarely left on more than 2 weeks, since it is immobilizing the shoulder, elbow, and carpal joints in rather severe flexion.

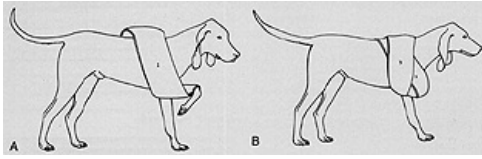


FIG. 15-3 Application of a Velpeau sling. (A) The Velpeau sling is shown with the first revolution in place. (B) The finished Velpeau sling, with the second and third wrap shown.

ROBERT JONES DRESSING

This bulky bandage for immobilization of an extremity, first used by Sir Robert Jones, was popularized in veterinary medicine by R.B. Hohn.

INDICATIONS

The bandage can be used as a temporary dressing for immobilization of fractures and is especially useful for traumatized extremities with a great deal of swelling or edema. The dressing is also used as a way of partially immobilizing joints following reconstructive surgery of the knee, such as cruciate or patella surgery. The principle involved in the fixation is that of a large bulky dressing wrapped very tightly to the extremity, providing supreme comfort and relative immobility of the injured site.

APPLICATION

The Robert Jones dressing is applied using absorbent cotton roll. Following application of a stirrup on the dorsal and ventral surfaces of the foot, one-pound rolls of cotton are wrapped firmly around the extremity such that approximately two rolls would be used in an average 40- to 50-pound dog (Fig. 15-4). This bulky bandage is then wrapped with elastic gauze or Kling so that it is firmly adherent to the leg (Fig. 15-4). Further compression of the bandage is accomplished with the use of elastic tape (Elastikon). The dressing should be applied quite firmly so that the finished configuration sounds like a ripe watermelon when tapped with a finger. The bandage can be left on for 10 days, at which time it should be changed if it is still needed. Loosening of the bandage occurs over this 10-day period, and to a great extent immobility is lost. This dressing is sometimes used following cast or splint removal, especially in tendon surgery, to allow gradual partial return to weight bearing. As the splint loosens over the 10-day period, weight bearing is increased slowly. It is important that the tape stirrup be applied and incorporated in the Elastikon when completing this dressing, since it is the stirrup that prevents the splint from falling off. When an animal is discharged wearing a Robert Jones dressing, it is important to caution the owner that the bandage must remain dry. If a dog is to be walked in a rainstorm or following very wet weather, we encourage the owner to place the limb in a plastic garbage bag to prevent soaking of the dressing. The bag can be removed when the dog is brought back indoors.

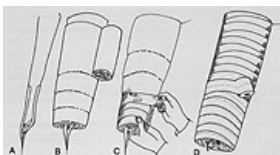

FIG. 15-4 Application of a Robert Jones dressing. (A) The tape stirrup is applied to the foot before the bandage is started. (B) Cotton roll is wrapped around a forelimb after the application of a tape stirrup (see Fig. 15-1) (C) Elastic gauze is then applied to firmly bind the cotton to the leg. (D) Elastic tape is then used to complete the dressing.

CRANIAL HALF CASTS

The cranial half cast is a very useful external splinting device for fracture of the hind leg distal to the stifle joint. For distal fractures of the tibia and injuries of the hock joint, this device can be used as the definitive means of immobilization. The cast is also useful in controlling rotation when using intramedullary pinning of proximal and midshaft tibial fractures. In proximal tibial fractures, the cranial half cast is used with a caudal shell as described under Functional Below-the-Knee Cast, below. To make a cranial half cast, plaster or thermal plastics can be used. To mold the splint, an exact impression of the cranial surface of the tibia, hock joint, and foot is needed. The leg should be kept in a relatively normal position with some flexion in the hock joint. The cast begins approximately at the level of the proximal portion of the patella and ends distally at the level of the toenails. The splint is made to encompass only the cranial half of the leg, and it must be molded accurately to provide the desired stability. Laterally the splint should cover the fibula throughout its proximal and distal length. On the medial side the splint should stop on the caudal surface of the tibia but should encompass the medial malleolus. The change in width of the splint as it proceeds distally is easily accomplished by raising a ridge along the anterior surface, which helps to strengthen the splint significantly. After the splint has been molded to the leg and cured, it may be applied to the leg with or without padding using elastic gauze, after taping the splint to the foot with a stirrup as described previously (Fig. 15-5). When applying the elastic gauze to coapt the extremity into the splint, care must be taken not to put undue pressure over the point of the hock. Pressure-point necrosis, which can be a complication at this juncture, is easily eliminated by proper bandaging. The necessity of the foot stirrup in attaching the splint is also important in preventing the splint from riding down over the medial or lateral malleolus, thereby providing additional pressure sores. The wrap should progress proximally until it is at the level of the tibial plateau. The cranial half cast can allow full range of motion in the stifle joint and still provide adequate stabilization in the distal third of the tibia.



FIG. 15-5 The plaster or thermal plastic cranial half cast is molded to the hind limb.

FUNCTIONAL BELOW-THE-KNEE CAST

When internal fixation is not used for fractures of the midshaft or proximal tibia, the addition of a caudal element over the upper portion of the splint is advantageous. Sarmiento has shown in humans that functional fracture bracing can occur with weight bearing while preserving motion of the joints.⁽³⁾ In the past 5 years we have modified his technique for the dog and have been able to adequately immobilize fractures of the tibia, including proximal one-third tibial fractures, at the same time providing motion in the knee joint and allowing healing to progress. Once the fracture is stabilized in the functional below-the-knee cast, severe excursions of motion at the fracture site can be eliminated. If, in fact, the reduction is shown to be adequate in postoperative radiographs, a functional below-the-knee cast can be used with confidence in any tibial shaft fracture. To make the Sarmiento-type cast, the anterior half cast is used along with a caudal member that flares out proximally and originates at the level of insertion of the gastrocnemius in the distal femur and extends distally to the end of the gastrocnemius muscle. It is important to flare the distal aspect also so that no impingement of soft tissue is made at the junction of the tendon and muscle. This caudal member is incorporated around the cranial half cast so that it will completely coapt the muscle mass of the gastrocnemius and upper tibia (Fig. 15-6). Theoretic considerations for this type of splint are based on the premise that fluids are incompressible and that completely immobilizing a muscle, which is really a fluid compartment, will allow more adequate immobilization of fracture fragments. Following reduction and incorporation in the Sarmiento-type cast, almost full range of motion of the stifle is preserved, but in the dog the hock is still immobilized. We have not used a brace to maintain motion of the ankle. Mobilization of this joint following fracture healing does not represent a problem in the dog as it does in humans. Normal weight bearing can proceed with the animal walking very well on the leg.

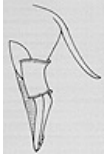

FIG. 15-6 The caudal plaster or thermal plastic member is added to the cranial half cast to become a functional below-the-knee cast.

SCHROEDER-THOMAS SPLINT

The Schroeder-Thomas splint became popular after Schroeder, working at the Angell Memorial Animal Hospital, reported on its use in the early 1930s.⁽⁴⁾ The splint was modified from its use in humans to more adequately fit the shape and conformation of the dog. The splint itself is a traction device that has proved useful in the treatment of fractures in small animals. The indications for the splint have changed considerably over the years but initially were quite broad. As better methods of fracture care were introduced, the indications for the Schroeder-Thomas splint became more limited. The improper use of the Schroeder-Thomas splint, resulting in nonunion of the fracture or joint stiffness (fracture disease), has given the device a poor reputation. In fact, application of the Schroeder-Thomas splint has been discontinued in some institutions because of poor results usually related to improper use. If properly fitted for suitable indications, the Schroeder-Thomas splint still represents an excellent tool for immobilization of fractures and in immobilization of joints following other surgical procedures. To optimally utilize this device it must be custom-made for each patient and requires constant attention and adjustment.

As stated above, the Schroeder-Thomas splint is a traction device. The splint is designed so that soft bandages (combine roll) are used as slings to properly position and counteract muscle forces to help align and immobilize parts of the skeleton. On occasion skin traction can be augmented with skeletal traction by using a transfixation pin. This is most commonly done at the stifle or the elbow joint. Here a pin is inserted through the condyles of the distal humerus or distal femur and traction is applied to the pins to control the distal fragment with a Schroeder-Thomas splint.

INDICATIONS

The Schroeder-Thomas splint can be used to immobilize any fracture distal to the midfemur or midhumerus. It is also a useful device for immobilization of joints distal to and including the knee and distal to and including the elbow. The indications for use of this splint can be extended in the hands of some veterinarians but to do so requires constant and careful supervision of the animal and its splint.

CONSTRUCTION

The Schroeder-Thomas splint is custom-made to each animal, and its shape changes in relation to the extremity injured and the purpose for which the splint is designed. In the hind leg the Schroeder-Thomas splint can be useful in immobilizing distal femoral or tibial fractures. Because most femoral fractures are usually stabilized by other means, the construction of the Schroeder-Thomas splint will be described for use in tibial fractures.

To make a Schroeder-Thomas splint it is necessary to have adequate supplies of material to complete the job. The frame of the splint is made of aluminum rods available in a variety of diameters. This external frame should be sufficiently stiff that it will not bend and deform when used by the animal in an appropriate manner. For the average 30- to 40-pound dog, a 6 foot, 3/8 in. diameter aluminum rod is used. The first important component to manufacture for the splint is the upper ring, which encompasses the thigh. The diameter of this ring can be determined by measuring the distance between the tip of the wing of the ilium and the point of the ischium. The ring should be constructed in a round fashion, which can usually be done by

fashioning the rod around an appropriate mold. These molds are available commercially or can be made in a large variety of sizes by using round wooden circles of 3/4 in diameter wood bolted together in sequence. Once the ring has been fashioned, the splint should be fitted to the animal. By lifting the leg it can be seen that the round splint will not conform to the medial side in the groin area. It is important, therefore, to bend the ring in an approximately 45° angle and flatten the ring so that it will conform to the dog's body. To do this, the lower portion of the ring is placed in a vice, and the bend is made approximately half way up the cranial border of the ring and approximately 1/3 of the way up the caudal border of the ring. This portion of the ring is then flattened and padded. Very little padding is needed. Tape is usually applied to the ring so that the sticky side is facing outward and a thin strip of cotton padding is wrapped around the tape. The tape is then reversed and the cotton is covered to protect it from becoming soiled and moist. The length of the Schroeder-Thomas splint is determined by the posterior member. While placing the dog's leg in a normal standing position, a right-angle bend is made at the distal end of the splint approximately 1 inch longer than the length of the dog's leg. It is important not to hyperextend the dog's leg when making this measurement; it should be in a normal position so that the splint will not be too long for the dog when walking. Since the Schroeder-Thomas splint is a traction device, it is important that its width be sufficient to allow traction of the individual members of the leg so that they will not contact the device itself. Bending of the bar in the cranial surface of the Schroeder-Thomas splint would be at the level of the knee and again at the level of the hock. It is important that this be done in a way that allows the padding to be appropriately placed. Following construction of the splint, the outside of the aluminum frame is covered with adhesive tape to prevent slippage of the traction slings before they are applied (Fig. 15-7). Combine roll is the usual choice of material for slinging the leg after fastening the distal end of the foot to the end of the splint by means of a taped stirrup. It is important that this tape be well fastened to the dog's foot because this is all that secures the splint to the dog's leg. It is equally important in application of the tape that no tape be placed in a circumferential manner that would cause constriction of the dog's foot and toes, possibly resulting in swelling or loss of vascularity and sloughing of the foot.

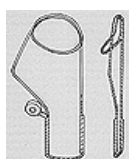

FIG. 15-7 A pelvic limb Schroeder-Thomas splint. The finished splint is shown with flattened tilted groin bar. Tape is applied to keep the traction members from slipping.

Following the application of the splint to the dog's foot by the cranial and caudal strips of tape, the hock joint is stabilized with the first band of combine roll, which is approximately the length of this splint. The combine roll is looped over the posterior aspect of the bar underneath or medial to the tarsus and the entire roll is brought around laterally so that the hock is pulled back into position. The hock is brought back so it touches the metal bar. The combine roll is continued around through the splint to provide medial support and is then pulled to tension and secured with tape (Fig. 15-8, A). At this point reduction of the fracture is accomplished and a second piece of combine roll, which is approximately 1 1/2 to 2 times the length of the splint, is used to secure the femur in a cranial position in relation to the splint (Fig. 15-8, B). In this case the procedure followed at the distal hock is repeated in reverse so that the femur is pulled forward to the bar, but after the combine roll has passed through the splint it then provides medial support to the tibial area by constant figure-of-eight motions within the splint (Fig. 15-8, C). Following tightening of the combine roll and taping it in place, the fracture is checked for stability. It is important that the ring of the Schroeder-Thomas splint be in contact with the groin area and not allow motion at the fracture site. Depending on the swelling that is present, it may be necessary to adjust the splint the following day and every three or four days thereafter.

When applying the Schroeder-Thomas splint to the hind leg, it is important to know for what purpose it is being applied. The shape of the splint is basically the same for any area, but traction should always be applied to the bone that is fractured or requires immobilization. The traction itself will not displace the fracture but will provide adequate tension on the already contracted musculature, thereby providing stability at the fracture site. When applying a Schroeder-Thomas splint for fracture of the tibia, the bands should go around the hock joint first and then above the femur area to provide traction of the tibia. If, in fact, the fracture is of the femur, the bands should go around the hock joint and then around the proximal tibia or distal femur to provide stability and traction in the femur. The traction exerted in the femur is provided between the bar under the groin and the uppermost traction band. Anytime a fracture is stabilized by means of a Schroeder-Thomas splint, valgus deformity is a possible complication unless care is taken to use medial support both in the tibia and femur when applying the second combine roll. The combine roll should always be directed at providing medial support to the fracture in question (Fig. 15-8, C). When applying a Schroeder-Thomas splint to the hind limb for fractures of the femur, it must be remembered that the proximal fragment of the femur will be in external rotation because of the pull of the iliopsoas muscle on the lesser trochanter. It is therefore imperative that the distal portion of the femur and the distal extremity be positioned in external rotation also. This will allow both the proximal and distal fragments to heal in external rotation, producing a straight leg. If, in fact, the distal fragment is held in its normal position with the leg in a normal position, the proximal fragment will rotate externally. This will result in a severe internal rotation deformity upon healing and a gait abnormality. When dealing with a femoral fracture, it is of utmost importance that care be taken to externally rotate the distal fragment in the first positional wrap.

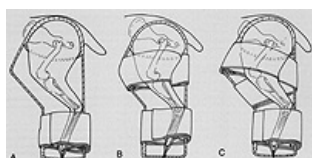


FIG. 15-8 Application of a Schroeder-Thomas splint. (A) The bottom sling is placed first, as shown. Following completion, the combine roll material is taped in place. (B) The process is reversed to apply the top combine roll to pull the femur forward, thereby applying traction to the tibia. (c) Medial support is applied to the tibia by continuation of the bandage medial to the tibia.

In femoral fractures it is common for the Schroeder-Thomas splint to change its shape slightly, becoming wider across its midsection. This will allow the femur and tibia to be at approximately a 90° angle at the knee joint, thus permitting the bands

to be applied to the tibia and thereby provide traction to the femur. If a larger angle is created between the femur and tibia (>90°), the bands may tend to slip down the tibia, providing inadequate immobilization of the fracture.

When completed, the Schroeder-Thomas splint may be covered by an elastic stockinette. This will help to prevent the animal from chewing on the device, as well as protect the device from being caught by projecting objects. However, covering the limb in such a way may make it difficult to determine if swelling has occurred. The basic method for checking swelling is to feel between the deep flexor tendons and the gastrocnemius muscle just above the point of the hock. If swelling has occurred here, the Schroeder-Thomas splint should be checked by careful observation and/or changing. Swelling should not be allowed to occur to a greater extent than mild pitting edema of approximately 2 days duration. Sometimes considerable edema is present at the time of splinting; if so, allowances must be made for this.

This Schroeder-Thomas splint applied on the front leg looks considerably different than on the back leg. The use of the Schroeder-Thomas on the front leg for distal humeral fractures, elbow fractures, or radial and ulnar fractures may allow for considerable change in the form that the splint takes. For midshaft humeral fractures, which are about the upper limit for use of this device, the splint will be relatively straight (Fig. 15-9). As the fracture becomes more distal, the positional shape of the splint will become more and more that of a right angle (Fig. 15-10) as the result of the relationship of the fractured fragments to the pull of the muscles that surround them. For midshaft fractures, direct traction on the leg will help reduce and immobilize the fracture fragments. When fractures occur at the distal end of the humerus, the extensors of the carpus and forepaw will rotate the distal fragment cranially. In this instance traction on the leg will produce a malalignment of the fractured humerus. The Schroeder-Thomas splint is made at a 90° angle, thereby allowing the fracture ends to be united in a more normal fashion. To make a Schroeder-Thomas splint for the front leg, the size of the ring is usually determined by the length of the scapular spine. The ring is flattened considerably into a large oval, and the distal aspect of the ring is bent medially to a 30° to 45° angle with the oval (see Fig. 15-9). The splint is padded, as it is in the back leg, and then bent according to the shape of the fracture. When bending the splint to the required shape it is important to seat the splint closely under the axilla while putting the elbow distally. The caudal bar of the splint should be bent at the elbow approximately 1 to 2 inches beyond the distal aspect of the elbow, and the cranial bar bent proximally 1 to 2 inches proximal to the elbow joint. This can be either a gentle bend, as in a midshaft fracture, or a right-angle bend, as in a distal humeral fracture (see Fig. 15-10). The length of the splint is determined by extending the leg in a relaxed manner so that the end of the splint will coincide with the end of the toe when extended to the splint. The foot is attached to the splint in the same manner as described for the hind foot, using tape on the cranial and caudal aspect of the paw. In the front leg, the wraps (combine roll) are applied first at the level of the elbow, pulling the humerus backward, and second at the level of the carpus, pulling it forward. This allows for a leverage effect that can increase the tension in the radius, ulna, or humerus when the second wrap is applied (see Fig. 15-10). Following the wraps the Schroeder-Thomas splint can be covered again with a stockinette. Adjustments are provided on the same time schedule as with the hind-leg Schroeder-Thomas splint.

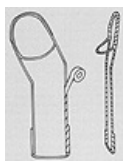

FIG. 15-9 The front-leg Schroeder-Thomas splint would assume this shape for a midhumeral fracture



FIG. 15-10 A right-angled Schroeder-Thomas splint. The first combine roll traction bandage is applied to the elbow region (1). The second traction bandage uses the first as a fulcrum and applies additional gentle traction to the humerus (2).

CASTING

Casts are a form of custom-made external immobilization that lie in contact with the skin and are made to conform to the injured part to act as a method of immobilization. Casts can be made for the entire body, as for spinal injuries, for any portion of the body (spica cast), or for just the extremities.

MATERIALS

Although there are many materials that are currently used in the manufacture of casts, plaster is still the most common in orthopaedics. In addition to being the most widely used, it is the cheapest material available. It has the advantage of being easily handled, with the ability to conform completely to any surface. Its strength capabilities are more than adequate for small-animal application, and its costs are reasonable. Other types of casting material are thermal plastics, fiberglass, and polyurethane-impregnated cotton polyester. All of these splinting materials have special advantages along with certain disadvantages. Their greater cost in comparison with plaster has not brought them into wide acceptance in small-animal veterinary practice.

APPLICATION

Although the technique of application of plaster casts can be described, the proper use of plaster is learned only by observing a skilled technician and by practical experience. Very few persons apply plaster in exactly the same manner, and the issue of whether to pad a cast is seldom a matter of agreement. Those that advocate applying padding under a cast do so based on the belief that padding reduces pressure sores and makes the cast more comfortable. Those that oppose padding express concerns about decreasing immobilization of the fracture and the possibility of creating, rather than

reducing, pressure sores as a result of rubbing or bunching of the padding. There is also concern about the coverage of toes or exposure of toes when using casting techniques. It appears possible to leave the central two toes exposed if, in fact, there is no weight bearing on the foot. If weight bearing occurs, the toes may become mutilated at the end of the cast. Often a walking bar can be applied to the end of the cast to prevent an animal from excoriating his foot or toes.

When applied to a leg in an encircling manner, the plaster is unrolled on the leg. It should not be pulled, stretched, or in any way tightened around the leg as it is applied. Usually the plaster can be set directly on the extremity and then just unrolled around it. As the plaster is applied, it should be done so in an even layer so that no thick or thin spots result. The plaster speed that is used for casting will usually be determined by the amount of cast material to be used. Small casts can take advantage of fast-curing plaster; larger casts may need a more slowly curing type. The water temperature also has a significant effect on the curing time of plaster: colder water allows the plaster to set more slowly while warmer water sets the plaster more quickly. With the various speeds of plaster that are available (slow, medium, fast, extra fast) and the water temperatures that can be used, a wide variety of setting times can be achieved. The strength of a cast material is proportional to its thickness. Often, additional reinforcing strips can be used along one surface to allow the cast to become strong without increasing the entire mass of the cast. These reinforcing strips, called splints, are used in large-breed dogs, especially over areas where angulation occurs which may result in fracture of the cast.

The following is a description of the application of a plaster cast to the foreleg for a fracture of the distal third radius and ulna. The animal is placed in lateral recumbency with the injured extremity down. This is done to help prevent valgus deformities at the fracture site, which easily occur when placing a cast on a leg on the up side. If reduction is necessary, general anesthesia is used and the area is shaved and prepped as for surgery in case penetration of the skin occurs during manipulation. The manipulation process is carried out using aseptic technique. Tape is applied to the foot on the dorsal and ventral aspects to provide a stirrup to hold the leg. The leg is elevated, and following reduction is attached to some support to maintain it in the elevated position. If the leg has been clipped previously, padding is used underneath the cast. This padding consists of two layers of specialist cast padding, which is wound around the leg from the distal to the proximal aspect in as tight a manner as is possible. Too much pressure applied to the specialist cast padding will result in tearing of the bandage, hence, no great care has to be taken to prevent overtightening of this layer. The padding can be increased to several more layers at the proximal aspect or end of the cast. A small stockinette bandage can be used underneath the padding if deemed necessary or appropriate. The cast material is rolled around the leg in such a way that it is always in contact with the extremity while it is being unwound. It is rolled from distal to proximal and should overlap itself on each encirclement of the leg. The amount of cast material necessary is dependent on the size of the animal. Following application of the plaster and while the plaster is still wet, the material is conformed to the shape of the leg and the leg is put in slight flexion of the carpus with slight medial deviation at the carpus. The slight flexion and medial deviation should occur at the carpus, not at the fracture site. This is important to prevent the occurrence of any valgus deformity, which may go unnoticed because of the normal laxity of the radial carpal joint. It is also of importance that during this positional change the metacarpal portion of the bandage be maintained in its proper alignment with no external rotation. The position of the forefoot should be neutral. Following application of the cast and proper positioning of the leg, the padding at the ends of the cast can be turned down and tape applied at the upper end as well as at the lower end over the stirrup to help maintain accurate position of the cast on the limb. Plaster takes considerable time to dry after it cures, hence, most animals should be held overnight and checked in the morning prior to release.

Cast materials can also be used for body coaptation casts or spicas, which incorporate the limb or part of the body to immobilize injuries to the proximal femur, proximal humerus or spine. These types of casts must be adequately padded and the plaster is applied in a figure-of-eight manner around the thorax and the limb in question. In some cases, to immobilize fractures of the pelvis, a 1 1/2 leg spica may be used as shown in Figure 15-11. In this case the pelvis was immobilized by being encased entirely in plaster, along with one leg and half of the other. This animal had presented with a severe comminuted fracture of the proximal femur that could not be adequately stabilized with a lesser cast.

Plaster can also be used for making splints. These splints are not totally encircling devices but may be applied to the limb and used as coaptation devices. Often in the front leg a double half cast is used such that strips of plaster run down the cranial and caudal aspects of the leg and are bound together with an elastic gauze or tape. This type of splint is of special advantage in the early immobilization of fractures accompanied by swelling because it allows release along the edges for increased swelling or tightening in case swelling decreases. It is also a very safe splint to use because it can be checked by weekly changing; thus it is a good choice for those who have little experience using plaster casts. The double half cast splint is usually applied in the same manner as the encircling cast and with the same preparation. The cast material is chosen according to the size of the animal and the length of the cast is that of the distance from the elbow to the tip of the foot. This distance is doubled, and approximately ten strips of plaster of this doubled length are laid on the table and torn halfway across in their midpoint. The plaster is wetted and placed on the leg from the toe up to the elbow. A uniform distance is kept between the cranial and caudal halves of the plaster, and a gauze bandage is wrapped around the plaster to provide conformity with the animal's leg. The same positional changes of flexion, slight medial deviation, and neutral rotation are maintained in the dog's carpus, and tape is applied to the splint after it has cured. Single splints can also be made with plaster using just a half splint. This is done routinely in the hind leg with a cranial half cast using plaster or one of the other casting materials. Thermal plastic is recommended in this position because of its ability to be reused and because it is impervious to water.

Ready-made plastic or aluminum splints can be used for fractures of the distal half radius and ulna. These splints are easily applied ([Fig. 15-12](#)).



FIG. 15-11 Illustration of a one and a half plaster spica. This cat sustained a comminuted fracture of the proximal femur including the femoral head.

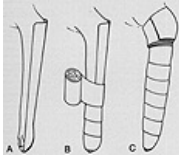


FIG. 15-12 Application of a metasplint. (A) A ready-made meta-splint is used to immobilize the forelimb. The device is often padded and may be used alone or with additional padding. The splint is usually attached with a foot stirrup, but some veterinarians attach it around the elbow with tape (B,C) Coaptation of the splint is done with gauze and tape.

[◀ Prev](#) [Next ▶](#) [Home](#) [Contents](#) [Glossary](#)

REFERENCES

1. Fowler NG: Canine limb supports. J Small Anim Pract 9:523, 1968
 2. Knecht CD: Application of temporary splints. Vet Clin North Am 5, No. 2:169, 1975
 3. Sarmiento A: A functional below-the-knee cast for tibial fractures. J Bone Joint Surg 49A:855, 1967
 4. Schroeder EF: The traction principle of treating fractures and dislocations in the dog and cat. North Am Vet 14:32, 1933.
-
-