

# Feline Castration

## Neutering the Male Cat:


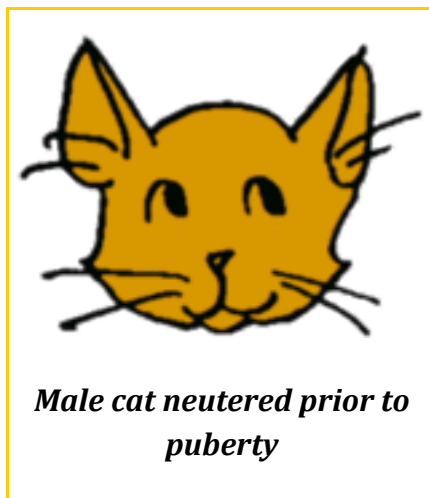
The main reason to neuter a male cat is to reduce the incidence of objectionable behaviours that are normal in the feline world but unacceptable in the human world.

*Roaming:* More than 90% will reduce this behaviour with neutering. Approximately 60% reduce this behaviour right away

*Fighting:* More than 90% will reduce this behaviour with neutering. Approximately 60% reduce this behaviour right away

*Urine marking:* More than 90% will reduce this behaviour with neutering. Approximately 80% reduce this behaviour right away.

Another reason to neuter a male cat has to do with the physical appearance. Cats neutered prior to puberty (most cats are neutered at approximately age 6 months) do not develop secondary sex characteristics. These include a more muscular body, thickenings around the face called shields, and spines on the penis.

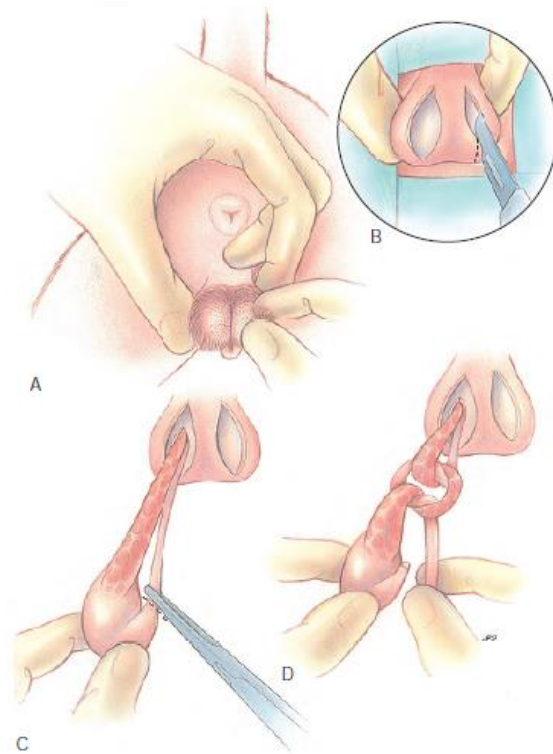


## Age for neutering:

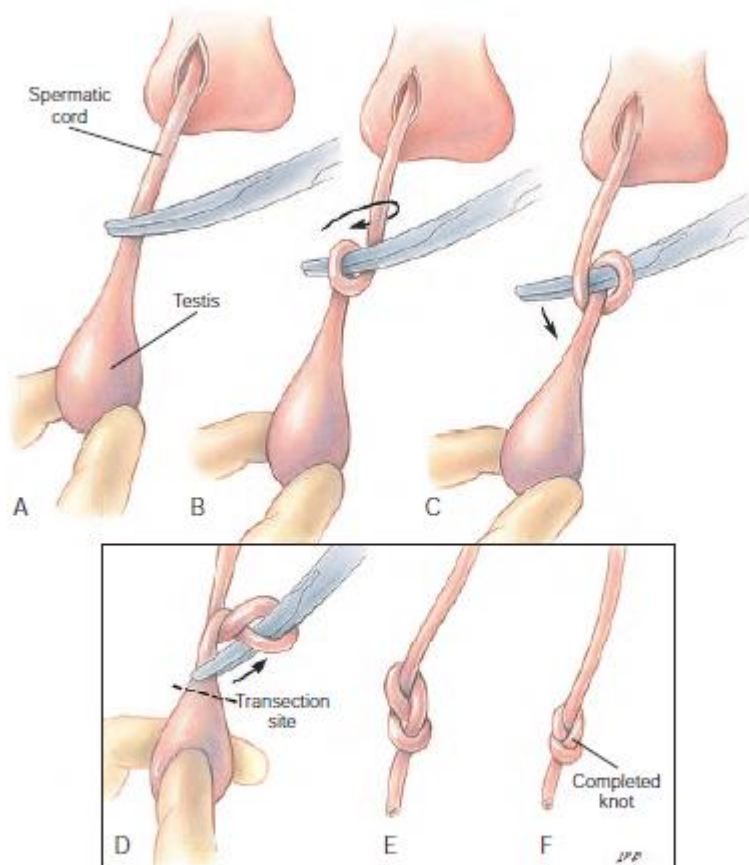
Traditionally male and female cats have often been neutered at six months of age, but this is after many cats reach sexual maturity and not based on any scientific rationale. For social, health and population control reasons, it is now recommended neutering should routinely take place at around 4 months of age.

### What is Done Exactly:

The feline neuter is one of the simplest surgical procedures performed in all of veterinary medicine. The cat is fasted overnight so that anaesthesia is given on an empty stomach. Pluck hair from the scrotum rather than clipping. In kittens less than 16 to 20 weeks of age, plucking scrotal hair may be difficult. Use clippers to gently remove scrotal hair in these animals. Position the cat in dorsal or lateral recumbency with the hind legs pulled cranially. Mobilize a testicle in the scrotum by applying pressure with the thumb and index finger at the base of the scrotum. Make a 0.5- to 1-cm incision over each testicle at the end of the scrotum from cranial to caudal. Incise the parietal vaginal tunic over the testicle and exteriorize the testicle. Digitally separate the attachment of the ligament of the tail of the epididymis to the vaginal tunic. Double ligate the spermatic cord with 3-0 absorbable suture or hemoclips, or remove the ductus deferens from the testicle and tie it with the vessels. Alternatively, use a figure-eight knot. Transect the cord, inspect for bleeding, and replace it within the tunic. Excise the second testicle in a similar fashion. Resect any tags of tissue protruding from the scrotum. Allow the scrotal incision to heal by secondary intention. Alternatively, to ligate the ductus deferens with the vessels separate the ductus deferens from the testicle. Using the remainder of the spermatic cord (testicular vessels and testicle) as one strand and the ductus deferens as the other, tie two to three square knots (five to six throws). Sever the vessels with attached testicle and ductus deferens distal to the knot. Inspect for haemorrhage. For an overhand or figure-eight knot, the spermatic cord is tied on itself with the aid of a curved mosquito haemostat. Preferably the parietal vaginal tunic is separated from the epididymis before tying the knot. Place the haemostat on top of the cord. Wrap the distal (testicle) end of the cord over the haemostat once. Direct the wrapped haemostat ventral to the cord while holding the testicle in the opposite hand. Open the tips of the haemostat, and grasp the distal end of the cord. Transect the spermatic cord near the testicle, and manipulate the severed end of the cord through the loops around the haemostat. Snug the knot, resect excess cord, inspect for bleeding, and replace the cord within the tunic before releasing.



**FIG 27-8.** **A,** For feline castration, pluck hair from the scrotum and aseptically prepare the scrotum for surgery. **B,** Make cranial to caudal skin incisions over each testicle. **C,** Incise and separate the parietal tunic from the testicle, then transect the ductus deferens near the testicle. **D,** Tie two to three square knots with the ductus deferens and the spermatic vessels.



**FIG 27-9.** An overhand technique may be used for feline castration. **A**, Place a curved hemostat on top of the cord and wrap the spermatic cord over it. Direct the hemostat's tip dorsally (**B**) and then ventrally (**C**) around the cord opposite the testicle. **D**, Next, grasp the cord near the testicle. **E**, Transect the testicle and pull the end of the cord through the wrap. **F**, Digitally snug the knot.

### Postoperative care:

Cats usually recover from the neutering operation remarkably quickly. They may be a little drowsy for a few hours, but by the next day they are usually very lively again. It is sensible to try to keep the kitten fairly quiet for a day or two to allow the internal wounds some time to heal. However, if the kitten seems unusually quiet or dull, should contact the vet. Also, if the kitten starts to lick or scratch excessively at the skin sutures, contact the vet to get a dressing or special collar to prevent any damage being done to the wound.

It is important to remember that once a cat has been neutered, there is a stronger tendency for it to become overweight. Therefore need to adjust the amount of food provided should the cat start to put on too much weight.

### Early Neuter?

A common animal shelter practice has been to adopt a young kitten with the new owner paying a neuter deposit to be refunded when the kitten is neutered at the traditional age of six months. The problem has been that new owners do not return and young cats go unneutered. Early neutering allows for kittens to be neutered prior to adoption. There has been some controversy over this practice as it flies in the face of tradition but all research to date has shown no negative consequences to early neutering.

Some **myths** have been:

*Early neutering is more likely to prevent objectionable behaviours than when done at a later age.*

This has not borne out. Neutering at any age is associated with the same statistics as listed above.

*Kittens neutered early will be stunted or small.*

This is not true, though early neutered kittens will not develop the more masculine appearance described above.

*Early neutered kittens will have a narrowed urethra that will predispose them to blockage with feline lower urinary tract disease.*

Early neutering does not seem to be a significant factor in this syndrome.

Some clinics support early neutering but prefer that kittens weigh at least 3 lbs. so that the tissues are not too difficult to manipulate.

### Recovery:

There is minimal recovery with this procedure. Some clinics discharge kittens the same day as surgery. There should be no bleeding or swelling. It is a good idea not to bathe the kitten until the incisions have healed for 10 to 14 days from the time of surgery.