

Transient non-cardiogenic pulmonary edema following massive ingestion of ethylene glycol butyl ether

Ph. Bauer¹, M. Weber¹, J.M. Mur², J.C. Protois², P.E. Bollaert¹, A. Condi¹, A. Larcen¹ and H. Lambert¹

¹Service de Réanimation Médicale et Centre Anti-Poisons, Hôpital Central, 54035 Nancy Cedex, France

²INRS, Centre de Recherche, Avenue de Bourgogne, F-54501 Vandoeuvre Cedex, France

Received: February 22, 1991; accepted: February 5, 1992

Abstract. A case of acute poisoning with ethylene glycol butyl ether (EGBE) is reported in a chronic alcohol abuser. On admission the 53-year-old patient was comatose with metabolic acidosis, shock, and noncardiogenic pulmonary edema confirmed by haemodynamic study. Following supportive treatment and haemodialysis the outcome was favorable. The relationship between respiratory failure and EGBE is examined.

Key words: Ethylene glycols – Poisoning – Pulmonary edema

Ethylene glycol monoalkyl ethers are widely used as solvents and diluents in resins, inks, perfumes and cleaning fluids [1]. Increasing informations on the human chronic toxicity are available; but few cases of human acute ingestion have been reported [2–6]. The pulmonary toxicity of ethylene glycol monoalkyl ethers has only been documented after repeated inhalation of ethylene glycol butyl ether in animals [7] and in one fatal case of ethylene glycol methyl ether poisoning by autopsy findings in man [2].

Case report

A 53-year-old man was admitted to the intensive care unit 10 h after attempting suicide with ingestion of 500 ml of a household cleaning fluid (GLASSEX®, RECKITT/COLMAN, Massy, France). Its composition was determined by gas-chromatography: the ethanol concentration was 2.5%, the EGBE concentration was 9.1% (45.5 g), there were only traces of diethylene glycol monoethyl ether. The patient was an alcohol abuser and neurotic with histories of trichloroethylene ingestions (14 and 4 weeks before that event). Vascular surgery had also been performed in the past.

On examination, after initial agitation, the patient was in a comatose state (Glasgow Coma Score 5/15). The heart rate was 105, blood pressure 60/30 mmHg, temperature 36.8 °C. Crackles were heard in both lungs. Transient polyuria was observed: 2500 ml in 2 h. Laboratory findings yielded the following values: metabolic acidosis and hypoxaemia (pH: 7.05, PaO₂: 26.8 mmHg, PaCO₂: 20.9 mmHg, HCO₃⁻: 5.6 mmol/l, SaO₂: 27.9%, room air) with lactic acidosis (calculated anion gap: 34 mmol/l, lactate: 5.3 mmol/l; serum osmolality was 305 mOsm/kg; potassium was 2.1 mmol/l; ASAT was 105 U/l, ALAT was 18 U/l, bilirubin was 8.5 µmol/l, ammonia was 83 µmol/l (normal

values below 44 µmol/l), prothrombin time was 15.5 s, with a control of 12.5 s; serum urea nitrogen was 9.99 mmol/l, serum creatinine was 115 µmol/l with slight albuminuria; salicylate concentration was 33.5 mg/l, no blood ethanol could be detected, serum EGBE concentration was 0.00528 mg/l. No EGBE was found in gastric lavage juice or urine. Urinary oxalate excretion was not followed.

The ECG showed a sinus rhythm; chest radiograph showed a diffuse pulmonary edema (Fig. 1). Bronchoscopy showed no bronchio-tracheal lesion which could go with an aspiration pneumonia. Hemodynamic data were consistent with ARDS (mean right atrial pressure –1 mmHg, mean pulmonary artery pressure +11 mmHg, mean pulmonary wedge pressure +1 mmHg); the arterial oxygen pressure was not corrected by oxygen supplementation alone (PaO₂: 48 mmHg, FiO₂:1). The pulmonary compliance was 33.5 ml/cmH₂O. The proteins in alveolar fluids (A) were 53 g/l and the total plasma proteins (P) were 71 g/l (A/P ratio: 74.6%).

Initial management included intubation, mechanical ventilation with increased FiO₂ (0.5) and positive end expiratory pressure (+10 cmH₂O), cardiovascular function support with colloids and epinephrine (0.5 µg/kg/min), sodium bicarbonate (750 mmol i.v.), ethanol (0.1 g/kg/2 h i.v.), gastric lavage with saline cathartic and hemodialysis (6 h) each time, three times, from 12th to 36th h.

The outcome was marked by a dramatic improvement of respiratory function within five days. Acidosis and hypoxemia were corrected in 4 h; shock was stabilized in 12 h. Epinephrine was suppressed on day 3 and PEEP was withdrawn on day 4. By 36 h after admission, biologic data showed a non hemolytic hypochromic anemia (hematocrit: 25%) with thrombopenia (platelet count: 85000). After 15 days the patient was discharged and had fully recovered.

Discussion

EGBE is a monoalkyl ether of ethylene glycol; the molecular formula is C₄H₉–O–CH₂–CH₂OH; it is completely miscible with water and most organic solvents [1]. EGBE is absorbed through the skin, lung and gastro-intestinal tract. The elimination half-time is brief (40 min) [8]. EGBE is oxidized by alcohol dehydrogenase in the liver. Its principal metabolite is butoxyacetic acid responsible for the metabolic acidosis. There seems to be an accessory pathway to ethylene glycol by hydrolysis [5].

EGBE appears more toxic than ethylene glycol monoethyl ether and ethylene glycol in animals [9]. Repeated exposure in animals caused pulmonary hemorrhage and liver injury [7]. There are few data available on

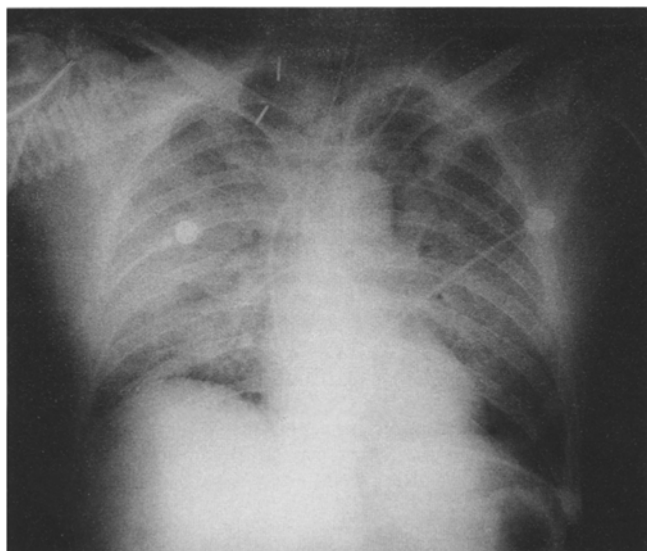


Fig. 1. Chest radiograph of a 53-year-old man on day 1 after ethylene glycol butyl ether poisoning

the toxicity of EGBE in man: coma, hypotension, metabolic acidosis, renal injury, hematuria and oxaluria [5, 6]. Repeated inhalations in animals have caused death. Dyspnea was the most usual sign of toxicity. Autopsy findings mainly consisted of congestion of the spleen, the liver, but also the lungs and the kidneys [7]. Volunteer subjects also complained of dyspnea.

This case reported the first case of adult respiratory distress syndrome (ARDS) after massive ingestion of EGBE. Meanwhile, Young et al. in 1946 [2] reported a case of fatal poisoning from ethylene glycol methyl ether with "slight edema and congestion of the lungs at autopsy findings". Nitter-Hauge in 1970 [4] related some "dry rales at the base of both lungs" in a man with ethylene glycol ethyl ether poisoning (Table I). There was no respiratory failure in the case studied by Rambourg-Schepens et al. [5] nor in the case studied by Gijsenbergh et al. in 1989 [6].

The main problem lies in the etiology and the pathogenesis of ARDS in this case: could it be the direct toxicity of EGBE or of one of its metabolites, or an aspiration pneumonia. As a coupling agent with excellent solvent

power, EGBE could impair the pulmonary membrane or the surfactant in case of massive absorption, but no data are available on this point. In fact it is not clear whether the findings in this patient were related to the toxicity of the compound or the severe unstable condition that he found himself in.

In the same way, abnormal liver function tests could be related to the initial shock in a chronic alcohol abuser or could be related to the direct toxicity of EGBE on the liver or presumably secondary to hemolytic effects [10]. The erythrocyte osmotic fragility is increased by EGBE in animals [1]; no information is patent in humans. A fall in haemoglobin was observed on the 2nd day in Gijsenbergh's case. On the 3rd day, anemia with hemoglobinuria was reported in Rambourg-Schepens's case. In this case, a non hemolytic anemia was detected; other mechanisms such as hemodilution were suggested.

In case of EGBE poisoning, treatment includes life support (respiratory, circulatory, renal function support) and prevention of absorption (Ipecac syrup, gastric lavage, activated charcoal, cathartic). Ethanol therapy or pyrazole administration have been suggested because of a competitive inhibition of alcohol dehydrogenase [10]. Hemodialysis can be useful to remove the toxic agent and its metabolites and to correct severe acidbase or fluid-electrolyte disturbance or in case of renal failure.

In conclusion, acute poisoning by EGBE could cause, not only hematologic, neurologic, renal and metabolic disturbances but also acute severe and transient respiratory failure, the mechanism of which is unknown.

References

1. Ecotoc (1982) The toxicology of ethylene glycol monoalkyl ether, and its relevance to man. Report no 4, Brussels
2. Young EG, Woolner LB (1946) A case of fatal poisoning from 2-methoxy-ethanol. *J Ind Hyg Toxicol* 28:267–268
3. Fucik J (1969) Poisoning by ethylene glycol monoethyl ether. *Pracov Lek* 21:116–118
4. Nitter-Hauge S (1970) Poisoning with ethylene glycol monomethyl ether. *Acta Med Scand* 188:277–280
5. Rambourg-Schepens MO, Buffet M, Bertault R, Jaussaud M, Journe B, Gillet B, Fay R, Lamiabie D (1987) Aspects métaboliques de l'intoxication aiguë par ingestion de butylglycol. *Arch Mal Prof* 48:121–122
6. Gijsenbergh FP, Jenco M, Veulemans H, Groeseneken D, Verberckmoes R, Deloos HH (1989) Acute butylglycol intoxication: a case report. *Hum Toxicol* 8:243–245
7. Carpenter CP, Pozzani UC, Weil CS, Nair III JH, Keck GA, Smyth JR HF (1956) The toxicity of butyl cellosolve solvent. *Arch Ind Health* 14:114–131
8. Johanson G, Kronborg H, Näslund PH, Byfält Nordqvist M (1986) Toxicokinetics of inhaled 2-butoxyethanol (ethylene glycol monobutyl ether) in man. *Scand J Work Environ Health* 12:594–602
9. Tyler TR (1984) Acute and subchronic toxicity of ethylene glycol monobutyl ether. *Environ Health Perspect* 57:185–191
10. Poisindex (1991) Toxicologic management: ethylene glycol butyl ether. Micromedex Inc, 67

Table 1. Synopsis of 3 cases of ethylene glycol butyl ether poisoning

	This case	Rambourg-Schepens's	Gijsenbergh's
Sex	Male	Female	Female
Age (years)	53	50	23
Ingested dose (g)	45	30–60	25–30
CNS depression	yes	yes	yes
Lung injury	yes	no	no
Liver injury	yes	no	no
Renal injury	no	yes	no
pH	7.05	7.23	7.08
HCO ₃ ⁻ (mmol/l)	5.6	5	2.4
Hematocrit (%)	25 (2nd day)	28.6 (10th day)	?
Hemoglobin (g/dl)	9.1 (2nd day)	9.7 (10th day)	8.9 (2nd day)
Outcome	Discharged	Discharged	Discharged

Dr. Ph. Bauer
Service de Réanimation Médicale
et Centre Anti-Poisons
Hôpital Central
F-54035 Nancy Cédex
France