


DIMENSIONS IN SURGERY



by SCOTT ANDERSON, DVM, Diplomate of the American College of Veterinary Surgeons, Diplomate of the American College of Veterinary Emergency and Critical Care, Diplomate of the American Board of Veterinary Practitioners
PHIL GILL, DVM, Diplomate of the American College of Veterinary Surgeons
LARRY LIPPINCOTT, DVM, Diplomate of the American College of Veterinary Surgeons
MARY SOMERVILLE, DVM, Staff Surgeon
SHARON SHIELDS, DVM, Staff Surgeon
RAVIV J. BALFOUR, DVM, Diplomate of the American College of Veterinary Surgeons
ERIN WILSON, DVM, Staff Surgeon

*Dimensions in Surgery
is now in its 17th year!*

Surgical Case Report:

Intestinal Surgery

EMPHASIS:

Enterotomy and intestinal resection/anastomosis are routinely performed in most veterinary practices. Gastrointestinal foreign bodies, intestinal neoplasia, intussusceptions, and penetrating trauma are all frequent indications for intestinal surgery.

In this paper we will review current techniques for surgery of the intestine.

PREOPERATIVE DIAGNOSTICS:

1. Complete physical examination.
2. Minimum data base: CBC, serum chemistry profile and urinalysis.
3. Radiography:
 - a. Two-view radiographs of the abdomen.
 - b. Contrast radiography: occasionally a barium upper GI study may be performed (to demonstrate obstruction or partial obstruction), or a barium enema may be performed.

AXIOM: *If a perforating intestinal lesion is suspected, the use of barium is contraindicated. A water-soluble contrast agent should be used in such cases.*

- c. Two-view thoracic radiographs: if malignant neoplasia is suspected, to check for pulmonary metastases.
4. Abdominal ultrasonography: to evaluate the primary lesion; in the

case of neoplasia, to determine if metastatic involvement is present in other organs.

5. Abdominocentesis: if effusion is present.
6. Diagnostic peritoneal lavage.
7. Fiberoptic endoscopy; if the suspected lesion is accessible by this means.

PREOPERATIVE CARE:

1. Indwelling cephalic catheter.
2. Intravenous anesthetic induction protocol.
3. Endotracheal intubation and inflate cuff.
4. Isoflurane inhalant anesthesia to effect
5. Lead II ECG and pulse oximetry monitoring during prep and surgery.
6. Clip and prepare the abdomen for aseptic surgery.
7. Cefazolin 20 mg/kg IV immediately preoperatively.

AXIOM: *Second generation Cephalosporins may be advisable for procedures of the ileum or colon.*

SURGICAL TECHNIQUE:

1. Midline laparotomy.
2. Perform an abdominal exploratory evaluating all organs and the entire

GI tract from the stomach to the colon.

ENTEROTOMY:

1. To minimize spillage of intestinal contents, have the surgical assistant digitally occlude the intestine proximal and distal to the incision.

AXIOM: *Bobby pins of varying sizes can be used as a very convenient, atraumatic intestinal forceps. These are more maneuverable and less difficult to work around than a Doyen atraumatic intestinal forceps.*

2. Stab incision on the antimesenteric border of the intestine.
3. Extend the incision with scissors, over a sufficient length to extract the foreign body without traumatizing the incision edges (See Figure 1).

AXIOM: *It is better to make a longer incision, permitting easy extraction of the foreign body, rather than trying to squeeze the foreign body out through a too small enterotomy.*

4. Full thickness appositional sutures of 3-0 or 4-0 mono-filament absorbable suture material are placed 3mm apart to close the enterotomy.
5. Alternatively, for a short enterotomy, a simple continuous pattern may be used.

continued on page 14

DIMENSIONS IN SURGERY

continued from page 13

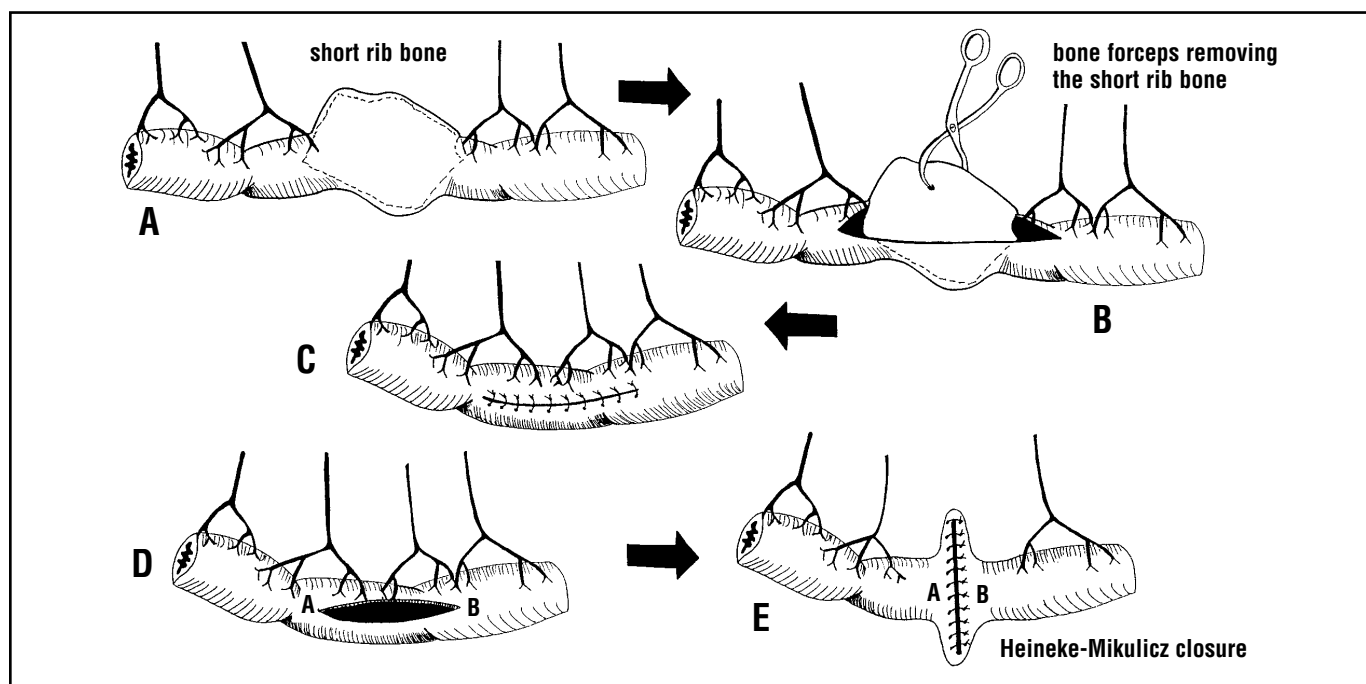


Figure One: This schematic drawing depicts: **A)** A large short rib bone lodged in the jejunum. **B)** The longitudinal enterotomy allows gentle removal of the foreign body. Note that the incision is longer than the object to be removed. Do not force a large object through a small incision. **C)** The longitudinal enterotomy is closed longitudinally. In a larger patient, this closure does not compromise the cross sectional diameter of the bowel lumen. This closure in a small patient will diminish the bowel lumen, and the Heineke-Mikulicz closure should be used. **D)** and **E)** outline the Heineke-Mikulicz closure pattern. **D)** The longitudinal enterotomy is closed transversely. **E)** This transverse closure, though bizarre looking, effectively increases the bowel lumen at the point of closure. See how **A** and **B** have changed.

AXIOM: For small patients, a Heineke-Mikulicz closure pattern may be used, closing the longitudinal incision transversely to minimize the risk of attenuating the lumen at that site (see Figure 1).

6. The integrity of the closure may now be tested by occluding the bowel proximal and distal to the closure site, and injecting a small amount of sterile saline solution into the intestinal lumen.
7. If the viability of the involved region of intestine is questionable, an omental patch or a serosal patch may be placed.
8. Liberally flush the area with warm isotonic saline solution.

AXIOM: For the remainder of the surgery, use fresh gloves and instruments, to avoid contaminating the tissues with bacteria from the intestinal lumen.

9. Routine abdominal, subcutaneous and skin closure.

RESECTION AND ANASTOMOSIS:

1. Determine the length of intestine to be removed.
2. Identify the mesenteric vessels that will be preserved.
3. Ligate the mesenteric vessels leading to the intestinal segment to be removed.
4. Using Bobby pins as described above, occlude the intestine proximal and distal to the surgical site (or, have the surgical assistant manually occlude the bowel).

5. Clamp the edges of the segment to be removed, to minimize spillage when the intestine is incised (see Figure 2).
6. Incise the mesentery (See Figure 2).
7. Transect the intestine to complete the resection.
8. Suction the exposed intestinal lumen at each end, to minimize spillage as the procedure is completed.
9. There are three methods to perform the anastomosis:
 - a. Sutured anastomosis:

1. place an interrupted full thickness suture at the mesenteric and antimesenteric borders, maintaining these as a stay suture (see Figure 3).
2. Place interrupted sutures at 3 mm intervals to complete the closure (See Figure 3). Alternatively, a continuous closure is preferred by some surgeons.

AXIOM: Do not pull the continuous suture too tight: this could create a purse-string effect, decreasing the intestinal diameter at the anastomotic site.

AXIOM: If the ends to be anastomosed are unequal in size, and a sutured anastomosis is to be performed, the narrower intestinal end should be cut obliquely (see Figure 3) to allow circumferential apposition.

continued on page 15

DIMENSIONS IN SURGERY

continued from page 14

b. Surgical stapling tools:

1. perform a side-to-side anastomosis of the antimesenteric borders using a GIA (gastro-intestinal anastomosis) device (See Figure 4).
2. Use a TA (thoraco-abdominal) stapler to close the open ends of the intestine (see Figure 4). This creates a side-to-side anastomosis that is functionally identical to an end-to-end anastomosis.

AXIOM: Place stay sutures at the points indicated to help manipulate the intestinal ends as the stapler is being applied.

- c. Skin stapler anastomosis (See Figure 5): this was recently reported in the Veterinary Surgery journal: a skin stapler, with staple size 5.7mm x 3.8 mm, is used to place staples instead of interrupted sutures.

6. The integrity of the closure may now be tested by occluding the bowel proximal and distal to the closure site, and injecting a small amount of sterile saline solution into the intestinal lumen.
7. If the viability of the involved region of intestine is questionable, an omental patch or a serosal patch may be placed.
8. Liberally flush the area with warm isotonic saline solution.

AXIOM: For the remainder of the surgery, use fresh gloves and instruments, to avoid contaminating the tissues with bacteria from the intestinal lumen.

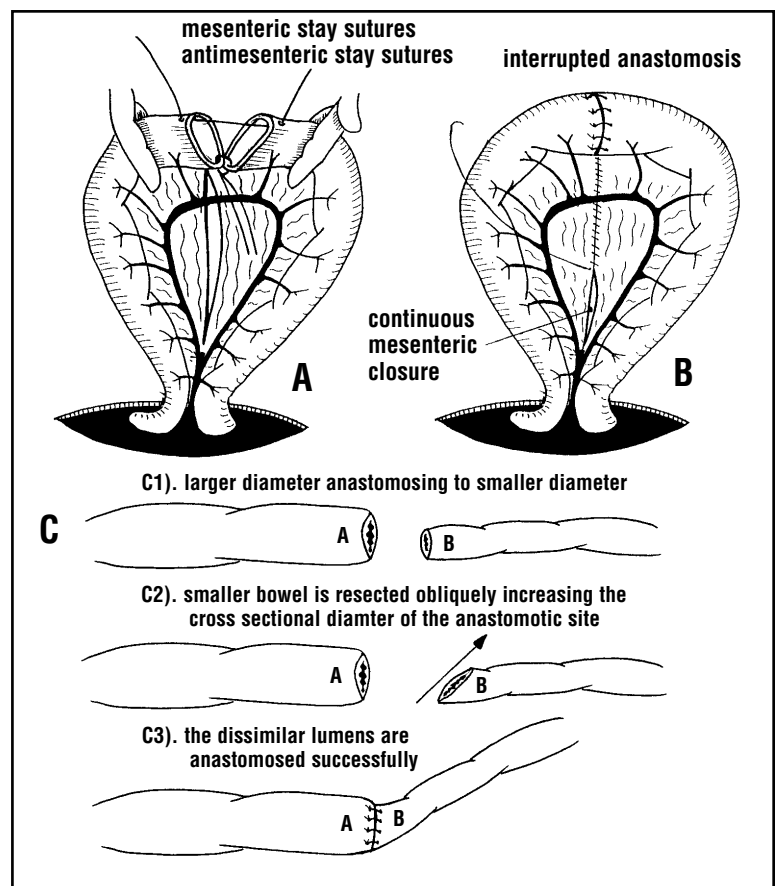
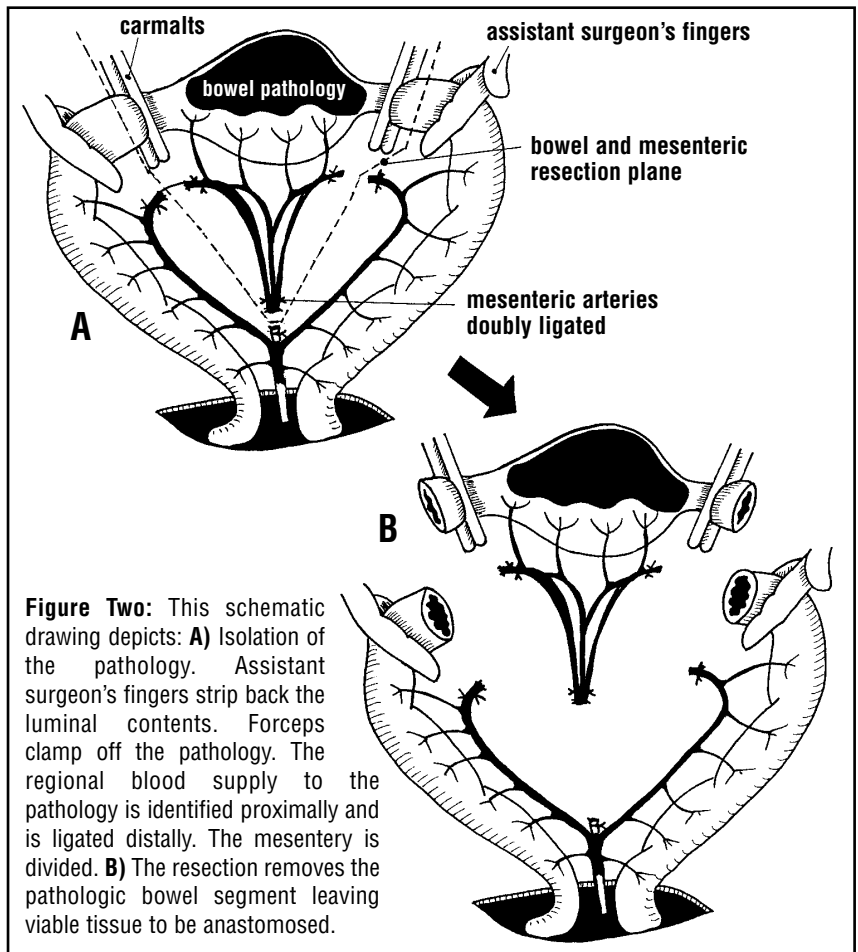
9. Routine abdominal, subcutaneous and skin closure.

POSTOPERATIVE CARE:

1. Pain management as needed using injectable, oral or transdermal analgesics.

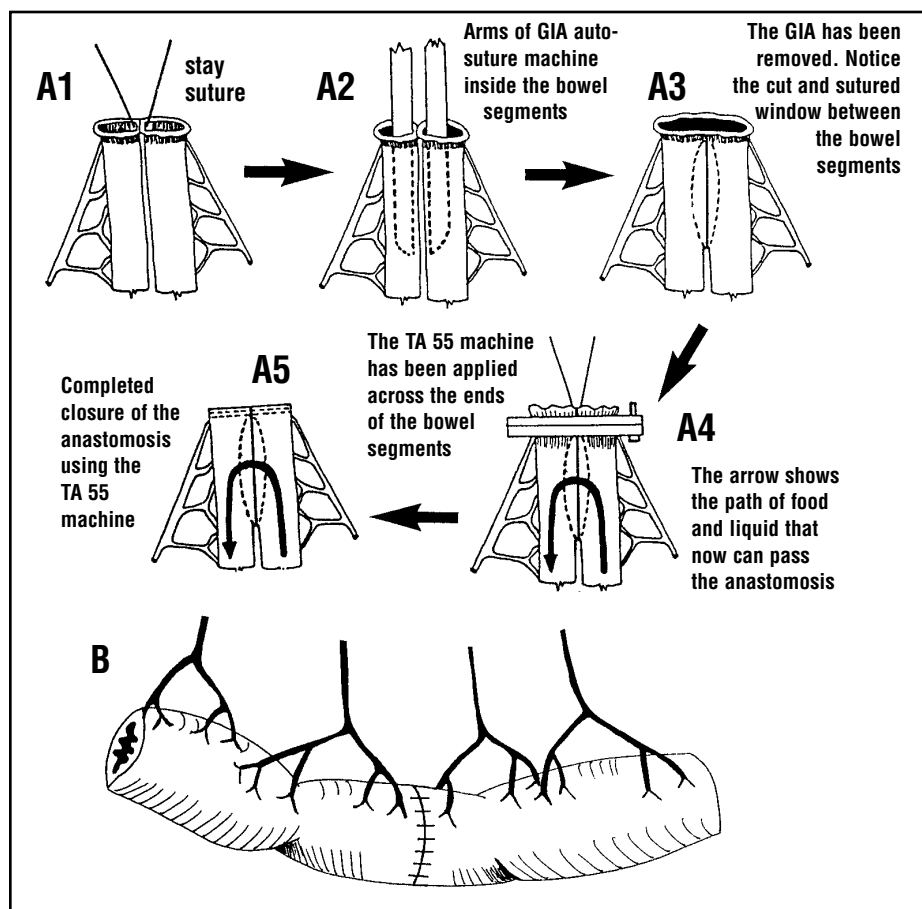
continued on page 16

Figure Three: This series of schematic drawings depicts various end to end intestinal anastomotic techniques: **A)** This drawing depicts the two approximated bowel lumens. mesenteric and antimesenteric stay sutures are placed to facilitate anastomosis. **B)** The intestine has been anastomosed and the mesenteric incision is being closed. **C)** This series demonstrates how to end to end anastomose lumens of differing cross-sectional diameter. **C1)** A has a larger diameter than does B. **C2)** B is obliquely resected to afford a larger bowel lumen. **C3)** A and B are anastomosed successfully.



DIMENSIONS IN SURGERY

continued from page 15



2. Broad spectrum antimicrobial treatment as per surgeon's judgement.
3. The patient may be fed 12 to 24 hours after surgery.
4. Suture removal 14 days postoperatively.

Figure Four: This series of schematic drawings depicts: **A)** (in the drawings **A1-A5**) The GIA (General Intestinal Anastomosis) and the TA (Terminal Anastomosis) machines are depicting anastomosing 2 bowel lumens. **B)** This end to end anastomosis has been done using a skin stapling machine.

AUTHOR'S NOTE

If you have any questions concerning this paper, additional references, surgical supplies or sources of products mentioned or used in this protocol, please FAX us at 1-310-479-8976. We will answer your questions promptly.

A Free Continuing Education Service Available:

- To obtain a free bound book containing recent "DIMENSIONS IN SURGERY" articles, merely mail your business card to us, and on the back write: "YEARLY SUMMARIES."
- Mail Your Card To:
 Larry Lippincott, Scott Anderson, and Phil Gill
 1736 South Sepulveda Blvd., Suite A
 Los Angeles, California 90025.
- We will send you a binder containing the "DIMENSIONS IN SURGERY" articles from the past two years, indexed and ready for quick office reference.
- Please be patient with the mailing of your articles.
- All first time "YEARLY SUMMARIES" requests received after January 2001 will receive the last two years' articles in one bound book.
- 24 of the most requested articles from the first three years of publication are still available and are contained in the *Practical Guide For Small Animal Surgery* book which can be obtained from the SCVMA office.
- The SCVMA now publishes *Dimensions In Surgery* articles and drawings on the Internet. Please visit us at: www.DVMPulse.com

Coming Attractions

Chylothorax is defined as the presence of chylous effusion in the thoracic cavity. It occurs when chyle escapes from the thoracic duct within the thoracic cavity. If trauma is the cause, the duct will often heal quickly and the chylothorax will resolve. More common etiologies include obstruction of the flow through the duct, due to neoplasm or other mass lesions, inflammatory disease or increased venous due to pericardial or cardiac disease. Chylothorax may also be seen with a diaphragmatic hernia or a lung lobe torsion. The majority of the cases are idiopathic.

Next month, we shall present our updated protocol for surgical relief of chylothorax
 See you then!