

Local and Regional Anesthesia in Cattle

Misty A. Edmondson, DVM, MS

*Department of Clinical Sciences, Auburn University College of Veterinary Medicine,
1500 Wire Road, Auburn, AL 36849, USA*

Although general anesthesia is commonly used in cattle, there are some risks with using general anesthesia. Local or regional anesthesia is safe, effective, and still the most desirable procedure in many situations. Many surgical procedures can be performed safely and humanely in cattle using a combination of physical restraint, mild sedation, and local or regional anesthesia. Local anesthetic techniques are usually simple, inexpensive, and provide a reversible loss of sensation to a relatively well-defined area of the body. Before local or regional anesthesia is performed, the animal should be adequately restrained. The type of restraint used depends on the temperament of the animal and the anesthetic technique to be used. Sedation may be necessary, however, in some cases. The site of injection should be prepared by clipping or shaving the hair and scrubbing and disinfecting the skin.

Local anesthetics

There are many local or regional anesthetics that vary in their potency, toxicity, and cost [1]. Two percent lidocaine hydrochloride and 2% mepivacaine hydrochloride have become the most commonly used local anesthetic agents in cattle because of low cost and limited toxicity. Lidocaine is three times more potent than procaine and diffuses more widely in the tissues. Lidocaine also has an intermediate duration of action from 90 to 180 minutes [2]. A vasoconstrictor, such epinephrine (5 µg/mL), added to the local anesthetic solution (0.1 mL of epinephrine [1:1000] to 20 mL of local anesthetic) increases the potency and duration of activity of both regional and epidural anesthesia. Local anesthetics containing epinephrine (1:200,000) should not be used in wound edges or in the subarachnoid space, however, because of the risks of producing tissue necrosis and spinal cord ischemia [3].

E-mail address: abramms@vetmed.auburn.edu

Anesthesia for dehorning

The corneal nerve block is used for anesthesia for dehorning cattle. The horn and the skin around the base of the horn are innervated by the corneal branch of the lacrimal or zygomaticotemporal nerve, which is part of the ophthalmic division of the trigeminal nerve. The corneal nerve passes through the periorbital tissues dorsally and runs along the frontal crest to the base of the horns. Approximately 5 to 10 mL of a local anesthetic agent is deposited subcutaneously and relatively superficially midway between the lateral canthus of the eye and the base of the horn along the zygomatic process (Fig. 1). Complete anesthesia may take 10 minutes. Larger cattle with well-developed horns require additional anesthetic infiltration along the caudal aspect of the horn, in the form of a partial ring block, to desensitize subcutaneous branches of the second cervical nerve [2,4,5].

Nasal anesthesia

The infraorbital nerve block may be used for the repair of nasal lacerations and the placement of a nose ring. The infraorbital nerve is the continuation of the maxillary branch of the fifth cranial nerve after it enters the infraorbital canal. The infraorbital nerve has only sensory function and emerges on the face as a flat band through the infraorbital foramen where it is covered by the levator nasolabialis muscle [2]. The infraorbital nerve is blocked as it emerges from the infraorbital canal. The nerve is difficult

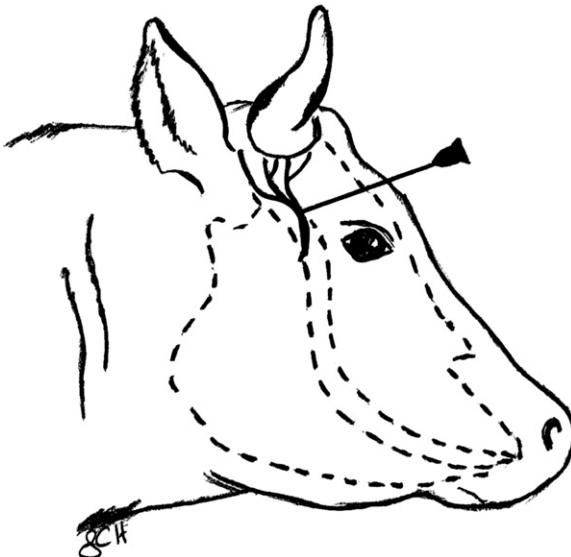


Fig. 1. Needle placement for desensitizing the corneal branch of the zygomaticotemporal nerve in cattle.

to palpate but is located rostral to the facial tuberosity on a line extending from the nasomaxillary notch to the second upper premolar. A total of 20 to 30 mL of local anesthetic agent is injected deep into the levator nasolabialis muscle with an 18-gauge 3.8-cm needle (Fig. 2). The injection should be repeated on the opposite side.

Anesthesia of the eye and eyelid and relaxation of the orbit

The globe, conjunctiva, nictitating membrane, and most of the eyelids are supplied by the ophthalmic branch of the trigeminal nerve. The extraocular muscles of the eye are innervated by the trochlear nerve, the abducens nerve, and the oculomotor nerve. The eyelids are innervated by the auriculopalpebral nerve. Topical and regional analgesia techniques are necessary for surgery of the eye and its associated structures, most commonly for squamous cell carcinoma, removal of foreign bodies from the cornea, and subconjunctival injections [1].

Anesthesia of the eyelid

Anesthesia of the eyelid is accomplished by performing a line block of the eyelid or by blocking the auriculopalpebral branch of the facial nerve. A line block is performed by using a 20- or 22-gauge 2.5-cm needle to inject 10 mL of a local anesthetic at multiple sites 0.5 cm apart on a line approximately 0.5 cm from the margin of the lid [1]. The auriculopalpebral nerve block

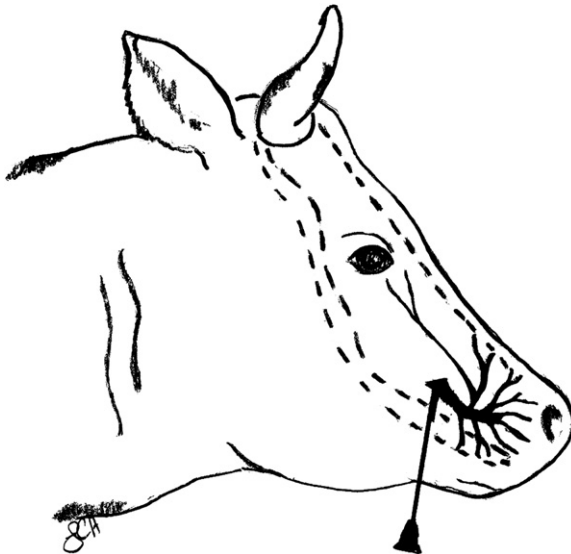


Fig. 2. Needle placement for desensitizing the infraorbital nerve in cattle.

is performed by using an 18- or 20-gauge 2.5-cm needle placed subcutaneously approximately 5 to 7.5 cm lateral to the zygomatic arch. A total of 5 to 10 mL of local anesthetic is then injected (Fig. 3) [2]. Because the auriculopalpebral nerve block only blocks the lower eyelid, if the surgical procedure to be performed also requires desensitization of the upper eyelid, a line block may be performed.

Anesthesia of the eye and orbit and immobilization of the globe

Anesthesia of the eye and orbit and immobilization of the globe that is necessary for such procedures as enucleation may be accomplished by performing a retrobulbar block or Peterson block.

Retrobulbar block

The retrobulbar block is used for enucleation of the eye or for surgery of the cornea, and when properly performed causes analgesia of the cornea, mydriasis, and proptosis. Adequate restraint of the head is necessary when performing this procedure. The sites for needle placement for retrobulbar injection are the medial and lateral canthus or the upper and lower eyelids [3]. An 18-gauge 15-cm needle is used and may be bent slightly to facilitate passage around the globe once it has been introduced through the eyelid or canthus at the orbital rim. The surgeon's finger is used to deflect the globe to protect it from the point of the needle (Fig. 4). Approximately 15 mL of local anesthetic is injected in small increments as the needle is advanced slowly toward the back of the orbit. The advantage of the

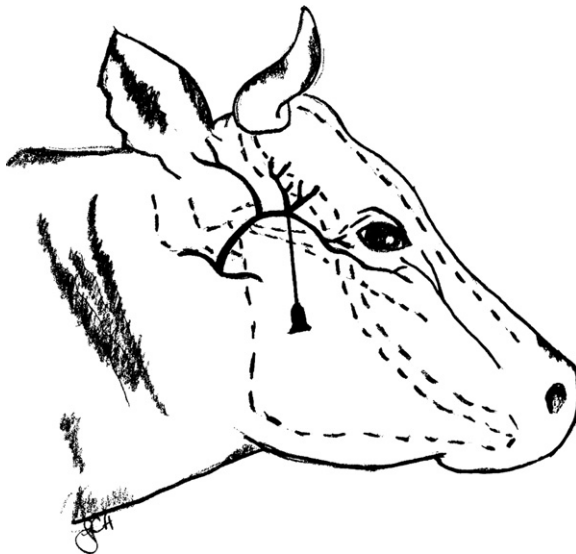


Fig. 3. Needle placement for desensitizing the auriculopalpebral nerve in cattle.

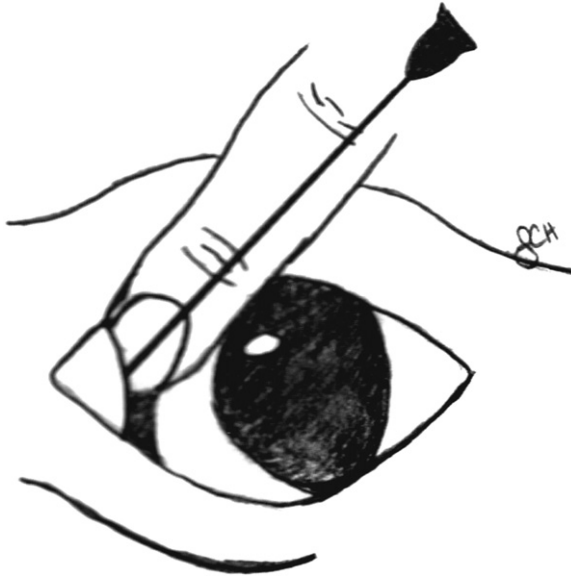


Fig. 4. Retrobulbar needle placement through the medial canthus of the eye in cattle.

retrobulbar block is that it is considered a much easier technique to perform. Some possible adverse affects of retrobulbar injections include penetration of the globe, orbital hemorrhage, damage to the optic nerve, dysrhythmias caused by initiation of the oculocardiac reflex, and injection into the optic nerve meninges [2].

Peterson eye block

The Peterson eye block requires more skill to perform than the retrobulbar block, but it is safer and more effective if performed correctly. There is also less edema and inflammation associated with this block than with infiltration of local anesthetics into the eyelids and orbit. The Peterson eye block desensitizes the nerves (oculomotor, trochlear, abducent, and trigeminal) responsible for sensory and motor function of all structures of the eye except the eyelid [2]. An auriculopalpebral nerve block can be performed to anesthetize the eyelid. The landmark for needle placement for the Peterson eye block is the notch that is created by the supraorbital process cranially, the zygomatic arch ventrally, and the coronoid process of the mandible caudally. Approximately 5 mL of local anesthetic is injected subcutaneously at this site using a 22-gauge 2.5-cm needle. A 14-gauge 2.5-cm needle serves as a cannula and is placed through the anesthetized area as far anterior and ventral as possible in the notch. A straight or slightly curved 18-gauge 10 to 12 cm is inserted into the cannula and directed horizontally and slightly caudally until it comes into contact with the coronoid process of the mandible at approximately 2.5 cm below the skin. The needle is then gently manipulated

rostrally until its point passes medially around the coronoid process. It is then advanced to the pterygopalatine fossa rostral to the solid bony plate that is in close proximity to the orbital foramen at a depth of 7.5 to 10 cm (Fig. 5). Penetration of the nasopharynx and turbinates should be avoided. Aspiration ensures that the ventral maxillary artery has not been penetrated [1,2]. Approximately 15 mL of local anesthetic is then injected.

Both the retrobulbar block and the Peterson eye block prevent blinking for several hours [1]. The cornea must be kept moist if these blocks are used for procedures other than enucleation. Caution must also be used with animals that are transported immediately following these procedures. A lubricating agent can be applied to the cornea, or the eyelids may be sutured together until motor function of the eyelids returns.

Anesthesia for laparotomy

Anesthesia of the paralumbar fossa and abdominal wall can be achieved by several techniques. These techniques include the proximal paravertebral nerve block, the distal paravertebral nerve block, the inverted L block, and infusion of the incision or line block. These anesthetic techniques are commonly used for such procedures as surgery of the digestive tract (abomaso-pxy, omentopexy, rumenotomy, volvulus, and so forth); cesarean section; ovariectomy; and liver and kidney biopsy.

Proximal paravertebral nerve block

The proximal paravertebral nerve block desensitizes the dorsal and ventral nerve roots of the last thoracic (T_{13}) and first and second lumbar (L_1 and L_2) spinal nerves as they emerge from the intervertebral foramina. To facilitate

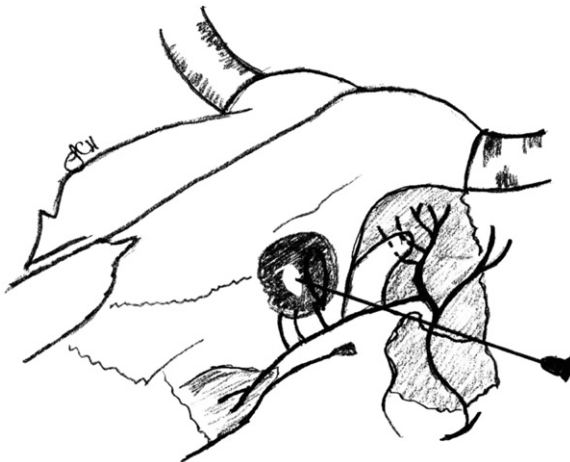


Fig. 5. Needle placement for the Peterson eye block.

proper needle placement of anesthetic, the skin at the cranial edges of the transverse processes of L₁, L₂, and L₃, and at a point 2.5 to 5 cm off the dorsal midline can be desensitized by injecting 2 to 3 mL of local anesthetic using an 18-gauge 2.5-cm needle. A 14-gauge 2.5-cm needle is used as a cannula or guide needle to minimize skin resistance during insertion of an 18-gauge 10- to 15-cm spinal needle. Approximately 5 mL of local anesthetic may be placed through the cannula to anesthetize further the tract for needle placement.

To desensitize T₁₃, the cannula needle is placed through the skin at the anterior edge of the transverse process of L₁ at approximately 4 to 5 cm lateral to the dorsal midline. The 18-gauge 10- to 15-cm spinal needle is passed ventrally until it contacts the transverse process of L₁. The needle is then walked off of the cranial edge of the transverse process of L₁ and advanced approximately 1 cm to pass slightly ventral to the process and into the intertransverse ligament. A total of 6 to 8 mL of local anesthetic is injected with little resistance to desensitize the ventral branch of T₁₃. The needle is then withdrawn 1 to 2.5 cm above the fascia or just dorsal to the transverse process and 6 to 8 mL of local anesthetic is infused to desensitize the dorsal branch of the nerve.

To desensitize L₁ and L₂, the needle is inserted just caudal to the transverse processes of L₁ and L₂. The needle is walked off of the caudal edges of the transverse processes of L₁ and L₂, at a depth similar to the injection site for T₁₃, and advanced approximately 1 cm to pass slightly ventral to the process and into the intertransverse ligament. A total of 6 to 8 mL of local anesthetic is injected with little resistance to desensitize the ventral branches of the nerves. The needle is then withdrawn 1 to 2.5 cm above the fascia or just dorsal to the transverse processes and 6 to 8 mL of local anesthetic is infused to desensitize the dorsal branch of the nerves (Fig. 6).

Evidence of a successful proximal paravertebral nerve block includes increased temperature of the skin; analgesia of the skin, muscles, and peritoneum of the abdominal wall of the paralumbar fossa; and scoliosis of the spine toward the desensitized side. Advantages of the proximal paravertebral nerve block include small doses of anesthetic, wide and uniform area of analgesia and muscle relaxation, decreased intra-abdominal pressure, and absence of local anesthetic at the margins of the surgical site. Disadvantages of the proximal paravertebral nerve block include scoliosis of the spine, which may make closure of the incision more difficult, difficulty in identifying landmarks in obese and heavily muscled animals, and more skill or practice required for consistent results [2,3,6].

Distal paravertebral nerve block

The distal paravertebral nerve block desensitizes the dorsal and ventral rami of the spinal nerves T₁₃, L₁, and L₂ at the distal ends of the transverse processes of L₁, L₂, and L₄, respectively. An 18-gauge 3.5- to 5.5-cm needle is inserted ventral to the transverse process and 10 mL of local anesthetic is

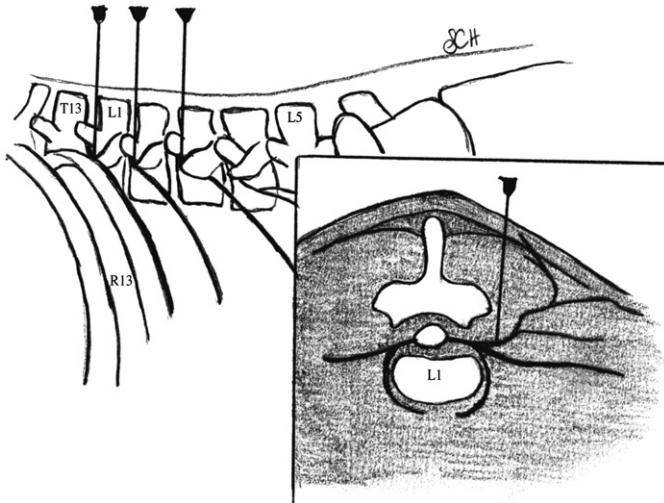


Fig. 6. Needle placement for the proximal paravertebral nerve block in cattle. Left lateral view and cranial view at the thoracolumbar junction. L1, first lumbar vertebra; L5, fifth lumbar vertebra; R13, last rib; T13, last thoracic vertebra.

infused in a fan-shaped pattern. The needle can then be removed completely and reinserted or redirected dorsally, in a caudal direction, where 10 mL of local anesthetic is again infused in a fan-shaped pattern. This procedure is repeated for the transverse processes of the second and fourth lumbar vertebrae (Fig. 7). Advantages of the distal paravertebral nerve block compared with the proximal paravertebral nerve block include lack of scoliosis, it is

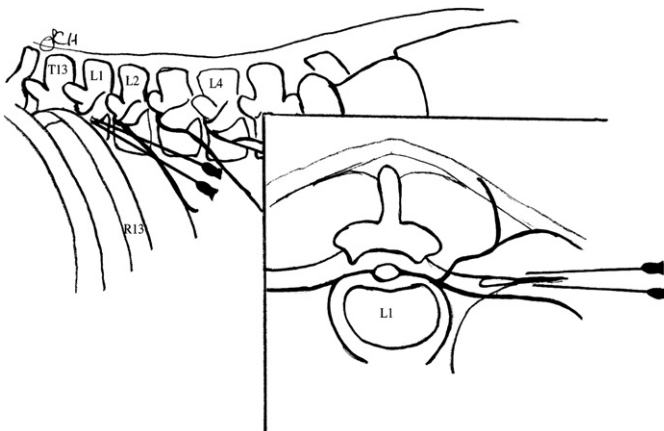


Fig. 7. Needle placement for the distal paravertebral nerve block in cattle. Left lateral view and cranial view at the thoracolumbar junction. L1, first lumbar vertebra; L2, second lumbar vertebra; L4, fourth lumbar vertebra; R13, last rib; T13, last thoracic vertebra.

easier to perform, and it offers more consistent results. Disadvantages of the distal paravertebral nerve block compared with the proximal paravertebral nerve block include larger doses of anesthetic required and variations in efficiency caused by variation in anatomic pathways of the nerves [2,3,6].

Inverted L block

The inverted L block is a nonspecific regional block that locally blocks the tissue bordering the caudal aspect of the thirteenth rib and the ventral aspect of the transverse processes of the lumbar vertebrae [6]. An 18-gauge 3.8-cm needle is used to inject up to a total of 100 mL of local anesthetic solution in multiple small injection sites into the tissues bordering the dorso-caudal aspect of the thirteenth rib and ventrolateral aspect of the transverse processes of the lumbar vertebrae (Fig. 8). This creates an area of anesthesia under the inverted L block. Advantages of the inverted L block include that the block is simple to perform, it does not interfere with ambulation, and deposition of anesthetic away from the incision site minimizes incisional edema and hematoma [3]. Disadvantages include incomplete analgesia and muscle relaxation of the deeper layers of the abdominal wall (particularly in obese animals); possible toxicity after larger doses of anesthetic; and increased cost because of larger doses of local anesthetic [3].

Line block

Infusion of local anesthetic into the incision site or a line block may also be used to desensitize a selected area of the paralumbar fossa. An 18-gauge 3.8-cm needle is used to infuse multiple, small injections of 10 mL of local anesthetic solution subcutaneously and into the deep muscle layers and

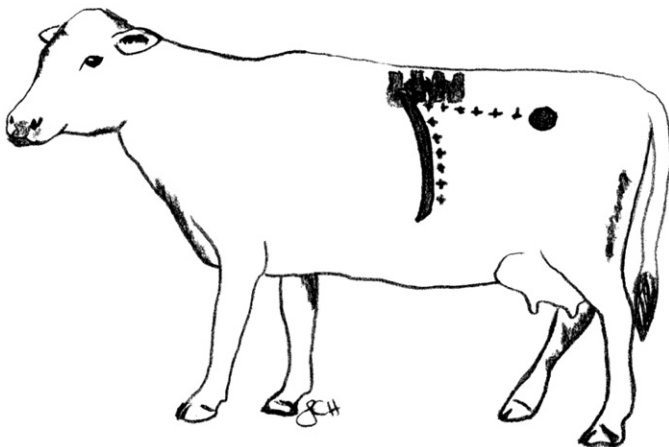


Fig. 8. Inverted L block for paralumbar anesthesia demonstrating multiple infusion sites (*), the last rib, the lumbar vertebra, and tuber coxae.

peritoneum. Pain of successive injections may be alleviated by placing the edge of the needle into the edge of the previously desensitized area at an approximately 20-degree angle [1]. In heavily muscled or overweight cattle, it may be necessary to use an 18-gauge 7.5-cm needle to penetrate through the large amount subcutaneous fat to reach the deep muscle layers. The amount of local anesthetic needed to acquire adequate anesthesia depends on the size of the area to be desensitized. Adult cattle weighing 450 kg can safely tolerate 250 mL of a 2% lidocaine hydrochloride solution [1]. Delayed healing of the incision site is a possible complication of infiltration of local anesthetic at the surgical site.

Anesthesia for reproductive procedures

Several anesthetic techniques have been used for obstetric manipulations and surgical procedures involving the tail, perineum, anus, rectum, vulva, vagina, prepuce, and scrotum. These techniques include caudal epidural anesthesia, continuous caudal epidural anesthesia, and internal pudendal nerve block. These techniques can also be used to relieve pain and control straining in cattle.

Caudal epidural

Caudal epidural anesthesia is an easy and inexpensive method of analgesia that is commonly used in cattle. A high caudal epidural at the sacrococcygeal space (S_5 – Co_1) desensitizes sacral nerves S_2 , S_3 , S_4 , and S_5 . The low caudal epidural at first coccygeal space (Co_1 – Co_2) desensitizes sacral nerves S_3 , S_4 , and S_5 ; as the anesthetic dose increases, nerves cranial to S_2 may also become affected [7]. If possible the hair should be clipped and the skin scrubbed and disinfected. Standing alongside the cow, the tail should be moved up and down to locate the fossa between the last sacral vertebra and the first coccygeal vertebra or between the first and second coccygeal vertebrae. An 18-gauge 3.8-cm needle (with no syringe attached) is directed perpendicular to the skin surface. Once the skin is penetrated, place a drop of local anesthetic solution in the hub of the needle (hanging drop technique). The needle should then be advanced slowly until the anesthetic solution is drawn into the epidural space by negative pressure. The syringe may then be attached to the needle and anesthetic solution slowly injected with no resistance (Fig. 9). The dose of local anesthetic to be used is 0.5 mL per 45 kg of body weight.

Continuous caudal epidural

Continuous caudal epidural anesthesia is used in cattle with chronic rectal and vaginal prolapse that experience continuous straining after the initial epidural. This procedure is performed by placing a catheter into the epidural

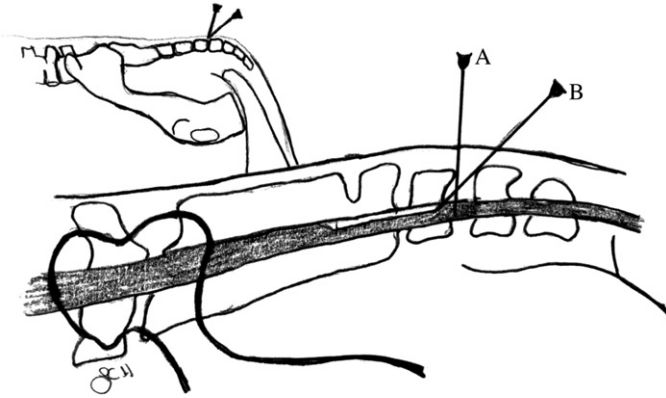


Fig. 9. Needle placement for caudal epidural anesthesia (A) and for continuous caudal epidural anesthesia (B) located between the first and second coccygeal vertebrae.

space for intermittent administration of local anesthetic. A 17-gauge 5-cm spinal needle (Tuohy needle) with stylet in place is inserted into the epidural space at Co₁ to Co₂ with the bevel directed cranial. The stylet is removed, and 2 mL of local anesthetic is injected to determine if the needle is in the epidural space. A catheter is inserted into the needle and advanced cranially for 2 to 4 cm beyond the needle tip. The needle is then withdrawn while the catheter remains in place (see Fig. 9). An adapter is placed on the end of the catheter and the catheter secured to the skin on the dorsum. Local anesthetic solution may then be administered as needed [1].

More recently, α_2 -agonists and opioids either alone or in combination with local anesthetic solutions have been used for epidural anesthesia. Epidural administration of the α_2 -agonist xylazine hydrochloride (0.05 mg/kg) diluted in 5 to 12 mL of sterile saline or xylazine hydrochloride (0.3 mg/kg) added to 5 mL of 2% lidocaine hydrochloride combinations offer similar anesthesia to lidocaine. Although the duration of anesthesia is prolonged (4–5 hours) using these combinations, systemic effects (sedation, salivation, ataxia) may also occur [3]. Epidural administration of opioids, such as morphine (0.1 mg/kg) diluted in 20 mL of sterile saline, is used to provide analgesia for a prolonged period (approximately 12 hours) without interfering with motor function. Disadvantages of using opioids for epidural anesthesia are that the analgesia is not as potent as lidocaine and the maximum effect of a morphine epidural may not occur for 2 to 3 hours. Caudal epidural administration of morphine may be used to help alleviate pain in the perineal area and straining [5].

Internal pudendal nerve block

The procedure for bilateral internal pudendal (pudic) nerve block was first described by Larson [8] to facilitate relaxation of the bull's penis without

causing locomotor impairment. The internal pudendal nerve block can be used in the standing bull for penile relaxation and analgesia distal to the sigmoid flexure and examination of the penis. In the standing female the internal pudendal nerve block can be used to relieve straining caused by chronic vaginal prolapse. This technique may also be used for surgical procedures of the penis, such as repair of prolapses, removal of perianal tumors, removal of penile papillomas or warts, and other minor surgeries of the penis and prepuce.

This procedure involves desensitizing the internal pudendal nerve and the anastomotic branch of the middle hemorrhoidal nerve using an ischiorectal approach. The internal pudendal nerve consists of fibers originating from the ventral branches of the third and fourth sacral nerves (S_3 and S_4) and the pelvic splanchnic nerves. The skin at the ischiorectal fossa on either side of the spine is clipped, disinfected, and desensitized with approximately 2 mL of local anesthetic (Fig. 10). A 14-gauge 1.25-cm needle is inserted through the desensitized skin at the ischiorectal fossa to serve as a cannula. An 18-gauge 10-cm spinal needle is then directed through the cannula to the pudendal nerve. The operator's left hand is placed into the rectum to the level of the wrist and the fingers directed laterally and ventrally to identify the lesser sacrosclatic foramen. The lesser sciatic foramen is first identified by rectal palpation as a soft depression in the sacrosclatic ligament. The internal pudendal nerve can be readily identified lying on the ligament immediately cranial and dorsal to the foramen and approximately one finger's width dorsal to the pudendal artery passing through the foramen. The internal pudendal artery can be readily palpated a finger's width ventral to the nerve. The spinal needle is held in the operator's right hand and introduced through the cannula in the ischiorectal fossa. The spinal needle is directed medial to the sacrosclatic ligament and directed cranioventrally (Fig. 11). The needle is not felt until it has been introduced approximately 5 to 7 cm and can then be repositioned to the nerve. Once at the pudendal nerve, 20 mL of local anesthetic is deposited at the nerve. The needle is then

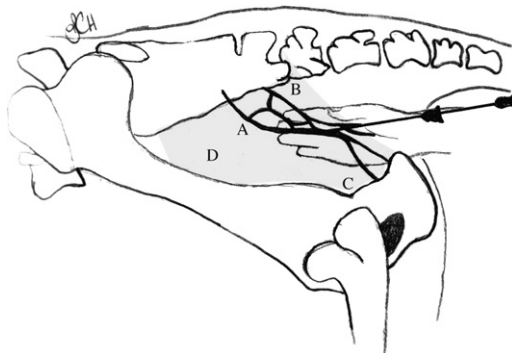


Fig. 10. Needle placement for the internal pudendal nerve block. (A) Internal pudendal nerve. (B) Caudal rectal nerve. (C) Internal pudendal artery. (D) Sacrosclatic ligament.

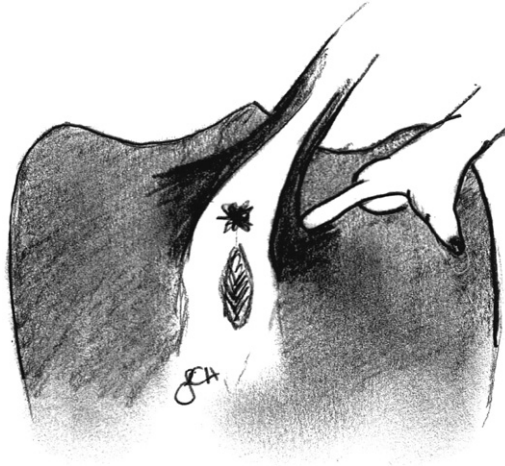


Fig. 11. Ischioanal approach for the internal pudendal nerve block. The injection site for the internal pudendal nerve block in cattle is at the point in the ischioanal fossa that is most deeply depressed with the surgeon's finger.

partially withdrawn and redirected 2 to 3 cm more caudodorsally where an additional 10 mL of local anesthetic is deposited at the cranial aspect of the foramen to desensitize the muscular branches and the middle hemorrhoidal nerve. The needle is then removed and the sites of deposition are massaged to aid in dispersal of the local anesthetic. This procedure is then repeated on the opposite side of the pelvis. Relaxation of the penis varies and may take as long as 30 to 40 minutes for full effect. The duration of the internal pudendal nerve block lasts from 2 to 4 hours.

Anesthesia of the foot

In many cases, intravenous regional anesthesia is the preferred technique for surgery of the foot. A tourniquet is placed proximal to the fetlock just before injection when the vein is maximally distended. In the thoracic limb, intravenous regional analgesia can be performed using the dorsal metacarpal vein, the plantar metacarpal vein, and the radial vein (Fig. 12). In the pelvic limb, the lateral saphenous vein or lateral plantar digital vein may be used for injection. Approximately 20 mL of local anesthetic is injected intravenously as close to the surgical site as possible using a 20-gauge 3.3-cm needle or 21-gauge butterfly catheter. It is only necessary to administer anesthetic into one vein to provide anesthesia to the entire area distal to the tourniquet. The tourniquet can be safely left on for up to 1 hour to provide hemostasis during surgical procedures of the foot. Anesthesia of the foot occurs within 5 to 10 minutes. Once the surgical procedure is complete the tourniquet is released.

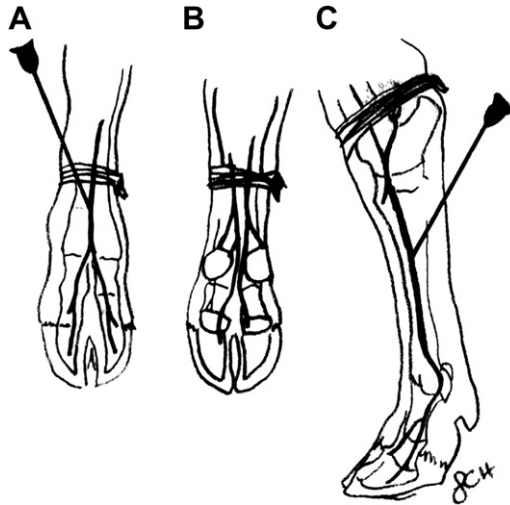


Fig. 12. Proper application of a tourniquet and placement of needle for intravenous administration of local anesthetic. (A) Dorsal metacarpal vein. (B) Plantar metacarpal vein. (C) Radial vein.

In cases of severe cellulitis, local intravenous anesthesia can be difficult to perform. In these cases, a simple ring block or four-point nerve block may also be performed. A ring block is a simple method for regional anesthesia distal to the injection sites. Using a 22-gauge 2.5-cm needle a total of 10 to 15 mL of local anesthetic is injected at multiple sites around the limb adjacent to the superficial and deep digital flexor tendons and medially and laterally to the extensor tendons. The ring block should be performed at the junction of the proximal and middle metacarpus or metatarsus. Although a simple technique to perform, multiple injection sites do increase the risk of infection. Problems achieving satisfactory or complete anesthesia of the digit may also be a concern when using a ring block [1]. The four-point nerve block anesthetizes the area from the pastern distally. A 20-gauge 3.8-cm needle is inserted into the dorsal aspect of the pastern, in the groove between the proximal phalanges, just distal to the fetlock. Five milliliters of local anesthetic injected deep and another 5 mL of local anesthetic is injected superficially. This injection is then repeated on the palmar or plantar aspect of the pastern, just distal to the dewclaws. Five milliliters of local anesthetic is then used to block the digital nerve on both the medial and lateral aspect of the fetlock, which lies approximately 2 cm dorsal and proximal to the dewclaw. The two interdigital injections performed in the four-point block may also be used for removal of an interdigital fibroma [5].

Anesthesia of the teat

Because most dairy cattle are accustomed to handling and restraint for milking, surgeries of the teat can often be performed with the animal

standing and with minimal restraint. Because standing procedures are always preferred to prevent udder trauma, most surgical procedures of the teat are performed using local anesthesia.

Inverted V block

The inverted V block is used primarily for specific lesions of the teat, such as a teat laceration or wart. Using a 25-gauge 1.5-cm needle, approximately 5 mL of local anesthetic is injected into the skin and musculature dorsal to the surgical site in an inverted V pattern (Fig. 13) [1,6].

Ring block

The ring block is a commonly used procedure for teat surgeries. Using a 25-gauge 1.5-cm needle, approximately 5 mL of local anesthetic is injected into the skin and musculature encircling the entire base of the teat (see Fig. 13) [1,6].

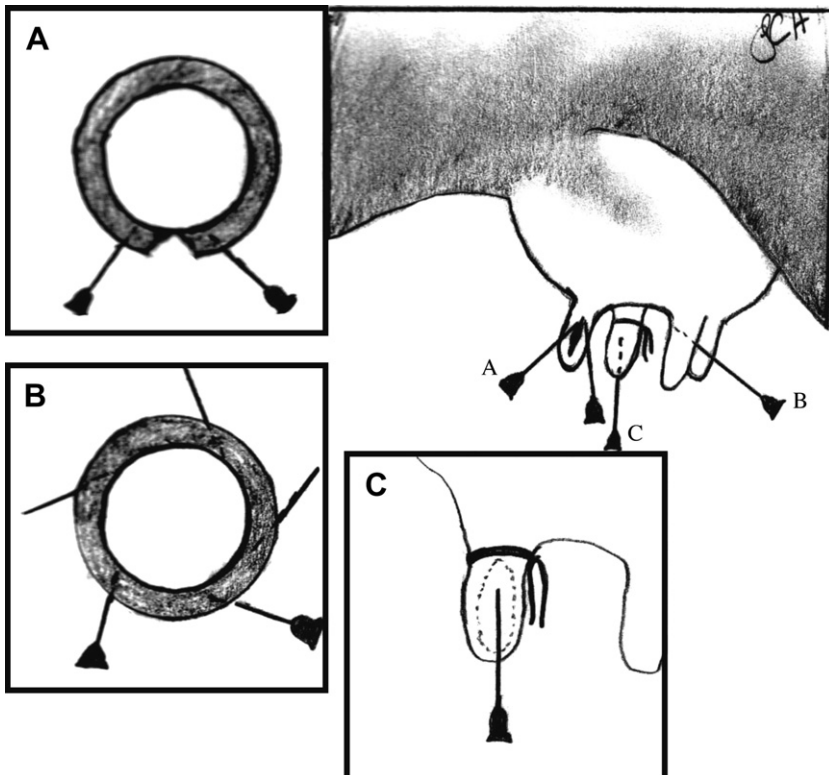


Fig. 13. Needle placement for teat anesthesia in cattle. (A) Inverted V block. (B) Ring block. (C) Placement of a tourniquet and teat cannula for infusion of local anesthetic into the teat cistern.

Infusion of the teat cistern

The teat cistern may be infused with local anesthetic to assist in surgical conditions that only involve the mucous membranes (eg, removal of polyps). Before infusing the teat, the cistern should be milked out and the orifice thoroughly cleaned with alcohol. A tourniquet (rubber band) is then placed on the base of the teat with adequate tension to prevent leakage between the udder and teat cistern. A sterile teat cannula is introduced and approximately 10 mL of local anesthetic is infused to fill the teat (see Fig. 13). The teat cannula is removed, and the remaining anesthetic is milked out. Once the surgery is performed, the tourniquet is removed. The musculature and skin are not desensitized using this technique [1,6].

Summary

Local and regional anesthesia techniques are safe and effective methods for providing anesthesia for common surgical procedures and painful conditions in cattle. These techniques are inexpensive and easy to perform and offer a safe alternative to general anesthesia in some cases.

Acknowledgments

The author thanks Jennie Carson Hill for providing illustrations.

References

- [1] Skarda R. Techniques of local analgesia in ruminants and swine. *Vet Clin North Am Food Anim Pract* 1986;2:621–63.
- [2] Edwards B. Regional anaesthesia techniques in cattle. *In Pract* 2001;23:142–9.
- [3] Skarda R. Local and regional anesthesia in ruminants and swine. *Vet Clin North Am Food Anim Pract* 1996;12:579–626.
- [4] Elmore RG. Food animal regional anesthesia, bovine blocks: cornual. *Vet Med* 1980;75:1610–2.
- [5] Navarre C. Numbing: nose to tail. *Proceedings from the 39th Annual Convention of AABP* 2006;39:53–5.
- [6] Noordsy J, Ames N. Local and regional anesthesia. In: Noordsy J, Ames N, editors. *Food animal surgery*. 4th edition. Yardley (PA): Veterinary Learning Systems; 2006. p. 21–42.
- [7] Noordsy J, Ames N. Epidural Anesthesia. In: Noordsy J, Ames N, editors. *Food animal surgery*. 4th edition. Yardley (PA): Veterinary Learning Systems; 2006. p. 43–55.
- [8] Larson LL. The internal pudendal (pudic) nerve block. *J Am Vet Med Assoc* 1953;123:18–27.