

Diagnosis of otitis media in dogs

Louis N. Gottself DVM

Animal Hospital of Montgomery, Alabama, USA

KEY POINTS

- Otitis media commonly occurs in older dogs with chronic otitis externa that resists topical treatment and in young cats with upper respiratory infections, or polyps, or both.
- Identification of the tympanic membrane is not always possible as it may not be present or it may not be visible through a stenotic ear canal.
- In otitis media, the tympanic membrane may be intact with significant disease within the tympanic bulla.
- Video otoscopy is a new technology now available that enhances the capability to visualise ear structures and to do procedures in the ear with excellent visualisation.
- Radiography is an important diagnostic tool in making the diagnosis of otitis media.
- When the ear canal is obstructed, advanced imaging techniques such as CAT scan or MRI can help evaluate disease processes proximal to the stricture and within the tympanic bulla.

Introduction

Identifying and treating otitis media in pets is a challenging situation for the veterinarian, a frustrating event in the pet owner's life, and a painful condition for the patient. When a veterinarian does not properly diagnose and treat otitis media, pet owners often seek second, third, and fourth opinions from neighbouring veterinary practices.

The diagnosis of otitis media in dogs can be quite difficult to make for a number of reasons:

- Dogs have a long, angled, funnel-shaped external ear canal making examination difficult

- Many patients with otitis media have an intact tympanic membrane (TM)
- Most dogs with otitis media also have a chronic otitis externa with pathological changes to the ear canal, making examination of the TM impossible (**Figure 1**)

Signalment and history

Acute otitis media is rarely found in the dog. It is uncommon for a patient to present to the veterinarian with acute otitis media. More commonly, a dog with otitis media will have a history of recurrent or chronic ear infections. Perhaps the pet owner will bring in all the ear medications already tried on the pet and that is a signal for the veterinarian to look deeper in the ear canal for middle ear disease.

Dogs with otitis media often have a liquid discharge present when the ear canal is examined with the otoscope (**Figure 2**). Some patients will produce so much exudate that it will overflow on to the periaural region of the face or, in a dog with pendulous pinnae, there will be dried exudate on the pinna adjacent to the external opening of the auditory canal. Head shaking to relieve the pruritus associated with liquid exudate is very common in otitis media. Pain may be apparent on palpation of the base of the ear canal or pain on manipulation of the pinna and this should also alert the clinician to otitis media.

Some patients with otitis media will be reluctant to have their mouth opened and there may be a history of reluctance to chew hard food. The horizontal ear canal is located adjacent to the temporomandibular joint and areas of inflammation and swelling within the soft tissues of the ear canal are compressed as the jaw is opened, resulting in pain.

When otitis media affects the nerves that course around and through the tympanic bulla the patient may show clinical signs such as keratoconjunctivitis sicca on the ipsilateral side. Rarely, there may be mild signs of Horner's syndrome (enophthalmos, ptosis, and miosis). If the



Louis N. Gottself
DVM

Dr. Gottself is a 1978 graduate of Tuskegee University, College of Veterinary Medicine and he owns Animal Hospital of Montgomery in Montgomery, Alabama. Over the past 12 years, Dr Gottself has taken an intensive interest in skin and ear diseases. He is a member of the American Academy of Veterinary Dermatology and has published a number of journal articles relating to ear diseases in dogs and cats. He has also been involved with clinical research, testing a number of veterinary dermatological drugs. He is the author of Small Animal Ear Diseases: An Illustrated Guide, published by W.B. Saunders.

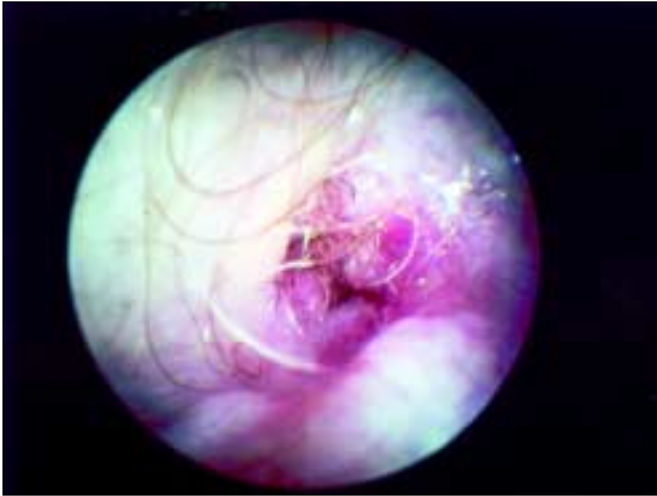


Figure 1 The ear canal of a 15-year-old miniature Poodle with chronic otitis externa and fibrotic hyperplasia. The canal is stenotic preventing otoscopic assessment of the TM.

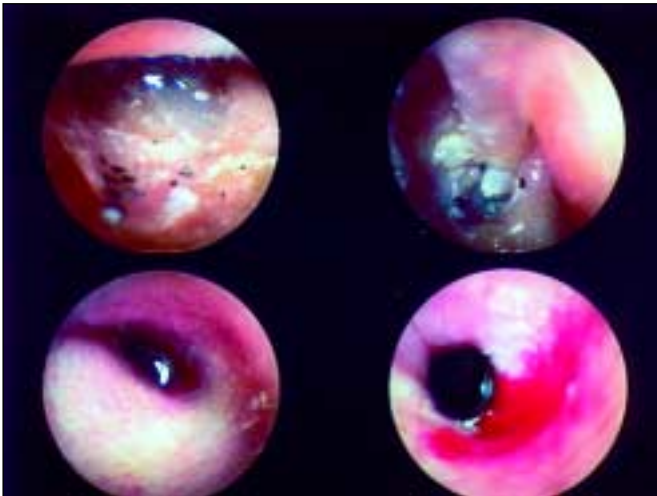


Figure 2 Otitis media is often accompanied by a discharge within the external ear canal. The discharge may be copious and may contain cerumen, tissue debris, hair, or inflammatory cells.

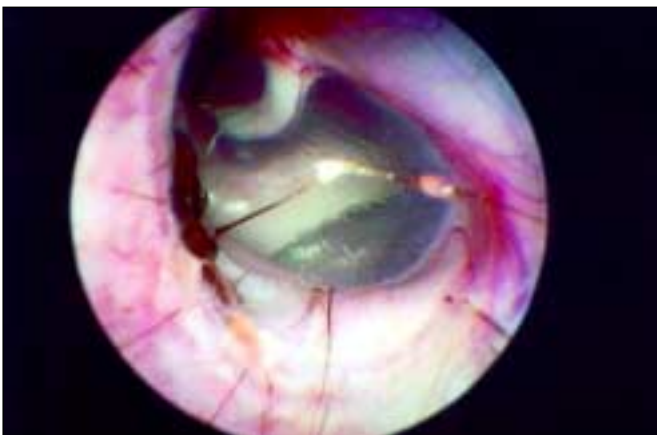


Figure 3 Normal canine TM (left ear). In the dorsal, upper right, quadrant is the pars flaccida—composed of loose connective tissue. The 'hook' of the malleus appears to originate in this region and then may be clearly seen against the translucent pars tensa, which accounts for most of the TM visible on otoscopy.

facial nerve has been traumatised either iatrogenically or by excessive pawing at the base of the ear, the dog may show pain, head tilt, drooped lip, drooped ear, or loss of the ability to close the eyelid, which may lead to exposure keratitis. Peripheral vestibular disease with nystagmus and circling may be evident if the infection and inflammation have affected the inner ear.

Some owners will present the dog for a hearing deficit. Fluid in the middle ear dampens acute hearing. When the TM is ruptured, or when the ossicles of the middle ear have sclerosed, air-conduction hearing is reduced. High-pitched sound waves cannot be effectively transmitted from the ear canal to the cochlea. If a tumour or a polyp has filled the middle ear, air-conduction hearing is eliminated. Bone-conduction hearing is usually still present in these patients, and the pet can hear only the lower range of tones.

If there is pharyngeal drainage of mucus and exudates, the patient may be presented for stridor. In these cases, a pharyngeal examination may reveal a nasopharyngeal polyp interfering with breathing or thick mucus covering the caudal pharynx occluding the airway.

Examination of the tympanic membrane

Examining the TM

The normal TM in the dog is a thin, translucent structure located at the end of the horizontal ear canal (**Figure 3**). It is composed of three layers. The outer layer, in the external ear canal, consists of a very thin layer of germinal epithelium one or two cells thick. The middle layer is primarily composed of collagen, to which the epithelium is attached. There are radial and circular collagen fibres in this thin supporting structure. The innermost layer is composed of a single layer of flat, squamous epithelium that is continuous with the cuboidal epithelium lining the tympanic bulla and covering the auditory ossicles.

In the dorsal portion of the TM is a loose tissue containing a network of blood vessels in a pattern that closely overlies the malleus bone. This is called the *pars flaccida*. The thin manubrium of the malleus bone is located on the medial side of the tympanum and extends from the dorsal portion of the TM ventrally, approximately halfway across the TM. It pushes into the medial side of the TM providing tension, permitting adjustment as sound intensity varies. This part of the TM is called the *pars tensa*. In the dog the TM is at an approximately 45- to 60-degree angle to the long axis of the horizontal ear canal.

Examination of the TM in the dog with otitis media requires general anaesthesia. If there is significant stenosis of the external ear canal, either from inflammation or from permanent pathological changes to the ear canal, the TM may not be adequately visualised. Potent topical glucocorticoids may be needed, for several days, to reduce otic inflammation sufficiently to allow examination of the TM. If permanent changes to the ear canal prevent visual determination of the integrity of the eardrum, other imaging techniques must be used to identify disease proximal to the stenosis.

Recently, the introduction of modern direct-imaging systems (such as the Video Vetscope) has allowed a very detailed, magnified examination of the ear canal and the TM. These modalities provide excellent lighting at the tip of the tapered probe and contain a high quality lens system that magnifies the image. The probe maybe coupled to a miniature video camera, which sends signals to a video monitor. The VideoVetscope, for example, has in addition a 2 mm instrument channel built into the probe, permitting procedures such as cleaning, or even biopsy, under excellent visualisation. The clinical photographs in this paper were taken with Video Vetscope.

Once the veterinarian is comfortable looking at the normal TM, and can



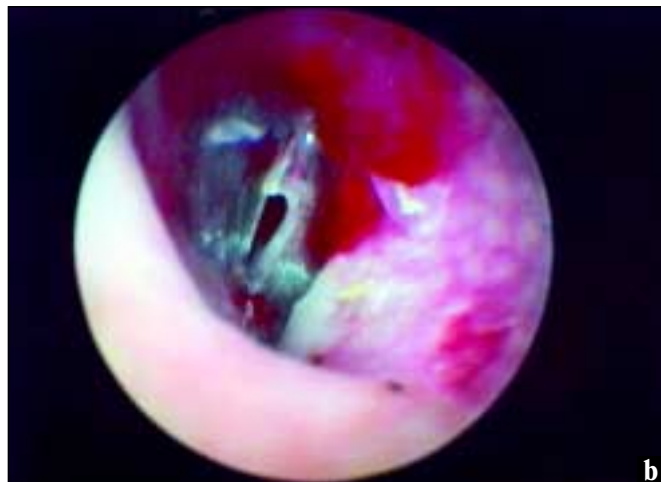
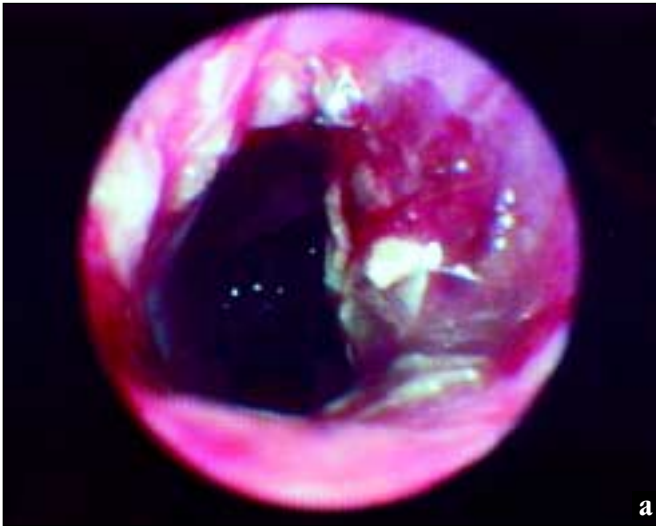

Figure 4 Ruptured TM: (a) Long-standing otitis externa in an elderly miniature Poodle has resulted in complete loss of the TM. (b) Here a rupture is plainly visible.

recognise normal location, colour, clarity, and tension, it becomes easier to diagnose otitis media.

In most cases of canine otitis media, there is no TM present. Most patients with otitis externa that has been present for 45–60 days will have a coexisting otitis media. In otitis externa, purulent exudates, and proteolytic enzymes elaborated by inflammatory cells, have a caustic effect on the epithelium of the TM, causing it to weaken and eventually rupture. When this happens, the debris, exudate, and infectious microorganisms in the external ear, may pass into the middle ear. In these patients it is difficult to visualise the TM since it may not be present at all (Figure 4a and b).

In some cases a large volume of exudate may accumulate adjacent to the TM. The TM loses its integrity, perhaps as a result of toxin accumulation, and bulges proximally into the middle ear. If it stretches significantly, the TM will adhere to the medial wall of the bulla and will fibrose, a condition termed false middle ear. Otolaryngoscopic examination reveals the absence of a TM at the end of the horizontal canal (Figure 5).

In some cases of otitis media the TM remains intact. Almost always, otitis media behind an intact TM results from unresolved otitis media in which the TM has healed, rather than representing primary or ascending infection. The inflammation and exude associated with acute otitis media

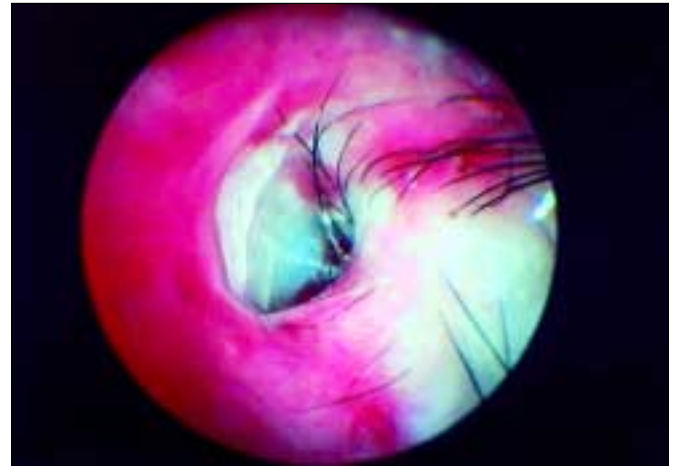


Figure 5 False middle ear. The TM in this German Shepherd Dog has been fibrosed on to the wall of the tympanic bulla and is no longer visible.

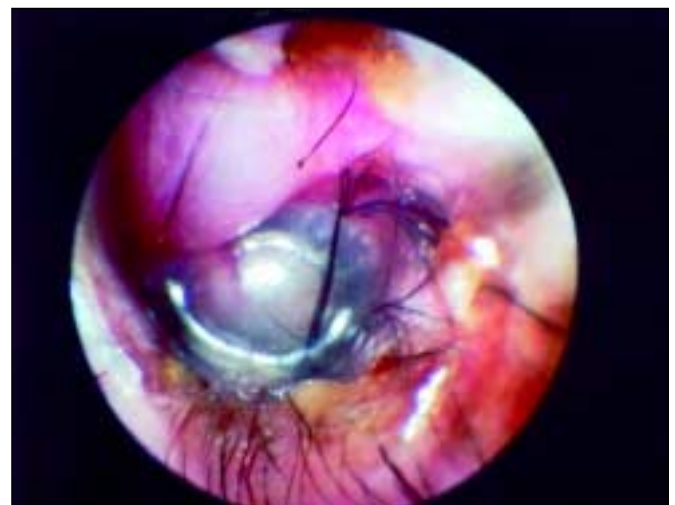

Figure 6 Bulging TM consequent upon inflammation within the middle ear. The pars flaccida is oedematous and is bulging distally, as is the pars tensa, which has lost its translucency.

has diminished, but the mucous membrane of the tympanic bulla has not returned to normal. Furthermore, infectious organisms and exudates are trapped within the bulla. The TM may change colour in response to inflammation on the medial side, becoming opaque and grey. Sometimes there is fluid behind the TM and examination of the intact TM may indicate that it is bulging into the external ear (Figure 6). Purulent material in the middle ear may be seen as yellow fluid behind the eardrum. Polyps, tumours, and masses in the middle ear may, occasionally, be seen as fleshy masses, visible through the TM (Figure 7).

Assessing the integrity of the TM

It is impossible to establish the integrity of the TM adequately by otoscopy (1, 2). Several techniques have been described to assess the integrity of the TM but many, such as insufflation, or probing with a Spreull needle, have been discredited as they may actually rupture an intact TM.

The author prefers to use a warmed, very dilute, solution of povidone iodine for evaluating the TM. To make this non-toxic flush solution, one or two drops of 1% povidone iodine are added to 250 ml warm tap water, primarily to add colour to the solution. The solution is gently infused into the horizontal ear canal of an anaesthetised dog in lateral recumbency with

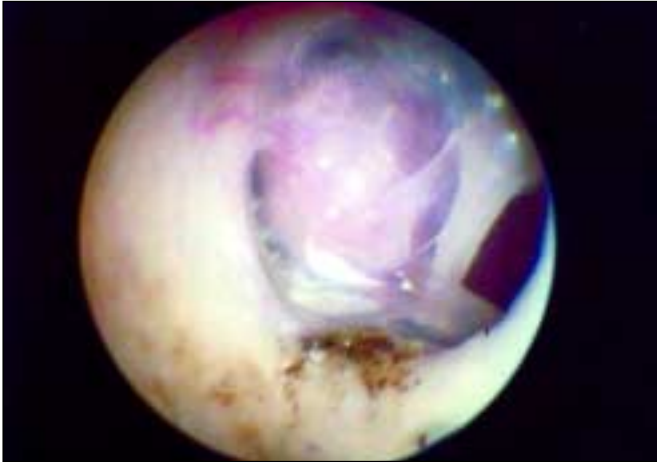

Figure 7 This otoscopic picture clearly shows a ruptured TM, behind which a mass is visible, within the middle ear.

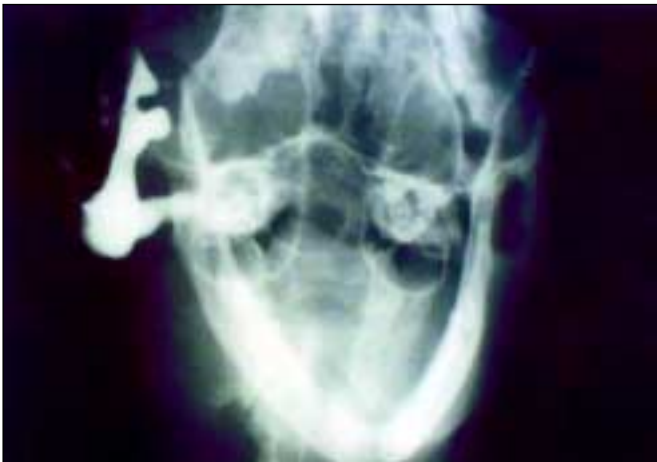

Figure 8 Positive contrast canalography. Otitis media, in this case in a cat, has resulted in the loss of the TM, permitting contrast media to enter the bulla.

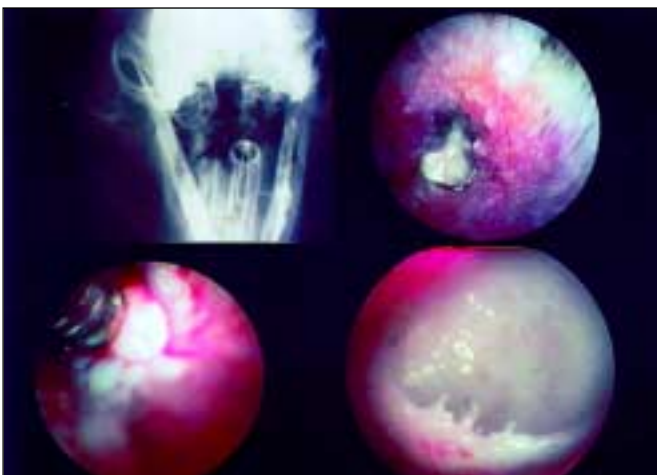


Figure 9 Radiograph and intraoperative otoscopy demonstrating chronic otitis media. The radiograph depicts a sclerotic bulla and the otoscopic pictures reveal absence of a TM and a thickened, granular appearance to the lining of the bulla.

the affected ear uppermost. If the pale orange flushing fluid emerges from the nostril, or into the oropharynx, the TM is ruptured. The liquid has filled the tympanic bulla through the ruptured tympanic membrane and has traversed the auditory tube, draining out through the external opening of the auditory tube, located in the oropharynx. In a patient that is lightly sedated, sneezing or choking, or both, may be seen.

Another technique used by some is to fill the ear canal with warmed saline and to insert the tip of the Video Vetscope into the ear canal. If air bubbles rise from the TM as the animal breathes then the TM must be ruptured, allowing air from the nasopharynx to escape from the middle ear.

Positive contrast radiography has been described as a method for detecting a ruptured TM in dogs with otitis media (3). Two to five millilitres of dilute iodinated contrast agent was instilled into the normal ear canals of cadavers with intact TMs, which had been intentionally ruptured. In every case, contrast media entered the tympanic bulla and was detected by radiography (**Figure 8**). In clinical otitis media cases, canalography was positive in most of the cases where the TM was determined to be ruptured otoscopically and was positive for other cases in which the TM appeared to be intact otoscopically. In normal ears, positive contrast canalography, as this technique is termed, was more accurate than otoscopy for detecting iatrogenic TM perforation.

Pathogenesis of otitis media

Once the contents of the external ear canal enter the middle ear, through a ruptured TM, inflammatory reactions occur within the respiratory epithelial lining. This has been termed secondary otitis media, to differentiate it from the ascending and primary aetiologies (4). Exudate and organisms draining into the middle ear through an eroded or ruptured TM tend to accumulate in the ventral portion of the bulla. The resulting suppurative inflammation causes the lining epithelium in the bulla, called the mucoperiosteum, to change from cuboidal to pseudostratified columnar, leading to an increase in the number of secretory cells and glands, whose activity further adds to the quantity of exudate. The lamina propria thickens in response to inflammation and, as vascularity increases, oedema and granulation tissue form. As otitis media becomes more chronic, the lamina propria changes to dense connective tissue (**Figure 9**) and bone spicules may develop within it. Not only does this tissue reaction occur in the bone of the tympanic bulla, but it also occurs on the auditory ossicles and they may become fused together, diminishing air-conduction hearing.

The exudates and secretions thus formed in the bulla escape into the external ear through the ruptured eardrum and contribute to the exudate already present in the external ear canal. Large amounts of discharge may be produced, sufficient to fill the ear canal and overflow on to the pinna at times. If there is a polyp or tumour blocking the outflow of secretions and exudates from the middle ear, significant quantities of inspissated material can be present when the obstruction is removed.

Patients with chronic otitis media may have had a history of repeated episodes of disease. Therapy is sufficient to reduce the inflammation and secretion, allowing the TM to heal. However, if the therapy is not sufficient to result in complete resolution of the otitis media it may continually flare up and the dog will exhibit cycles of otitis media and externa.

A recent study by Cole (5) demonstrated that in 70% of cases with otitis media the TM were intact and that the antibiotic sensitivity of organisms isolated from the horizontal ear canal were different from the antibiotic sensitivity from organisms from the middle ear. Almost 80% of these cases of otitis media cases had different isolates or antibiotic sensitivity patterns between the middle ear and horizontal ear canal. The most common isolates were *Staphylococcus* spp. and *Pseudomonas* spp.

Antibiotic sensitivity testing of the flora within the middle ear is



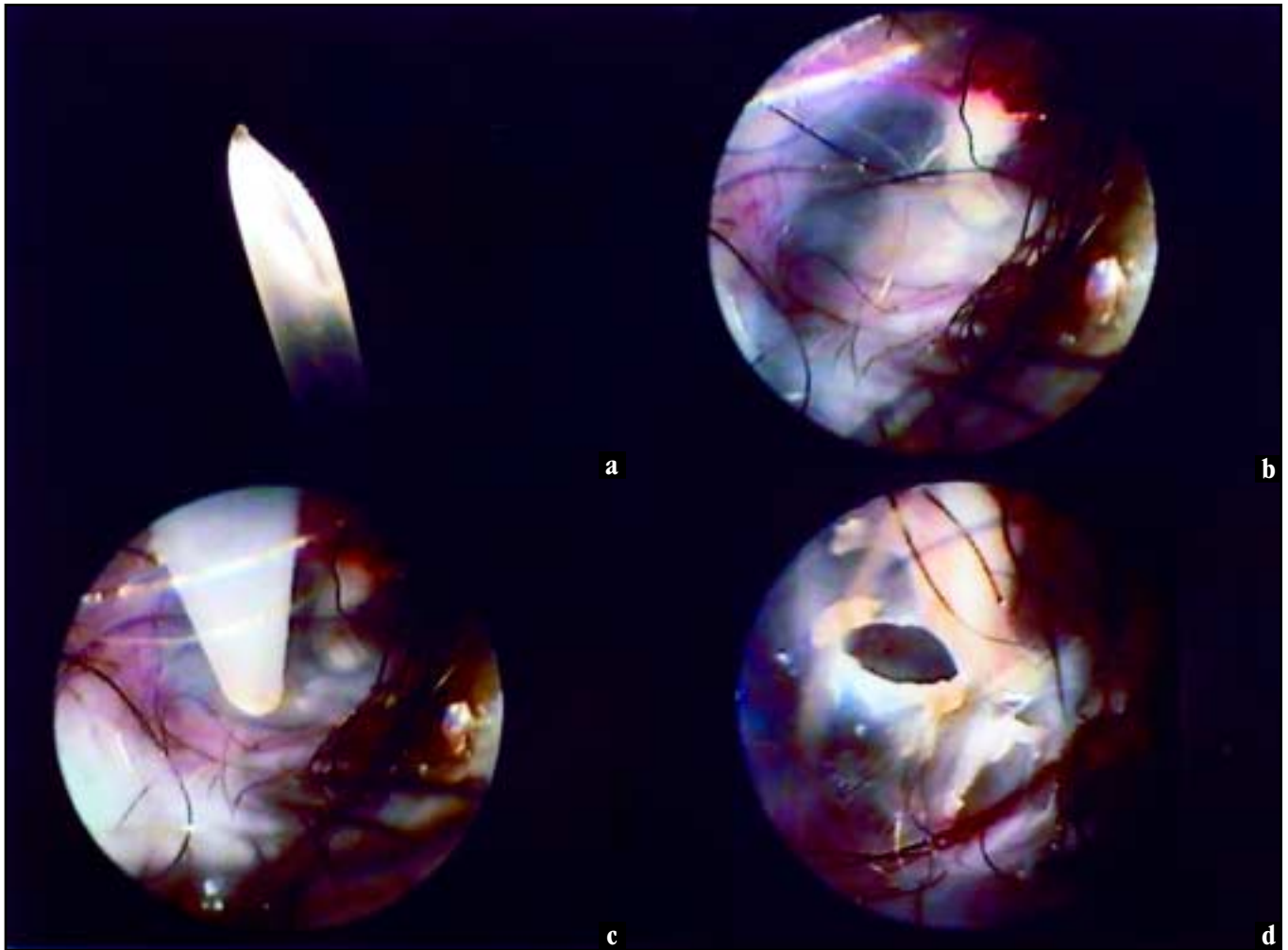


Figure 10 Procedure for myringotomy (a) A catheter (in this case 3.5 Fr) is cut to provide a point. (b) Under good visualisation the malleus is located. (c) The point is inserted so as to avoid the malleus. (d) The puncture is small, controlled and should not rip.

important in treating otitis media because systemic antibiotics must be used for long period of time. Although topical antibiotics can be infused directly into the tympanic bulla (and may achieve 100 to 1000 times the MIC) this is normally practical only if the animal is under anaesthesia, or has a drain implanted.

Myringotomy

Myringotomy may be indicated to establish a diagnosis of otitis media or to obtain samples for microbial culture and sensitivity testing. To perform a myringotomy, the patient is anaesthetised and the external ear canal is thoroughly cleaned with a disinfectant such as dilute povidone iodine. The ear canal is then dried using suction. A sterile rigid polypropylene catheter is cut to a 60-degree angle with a scalpel blade, to provide a sharp point. Alternatively a long, spinal needle can be used. The tip of the cut catheter, or spinal needle, is advanced *under good visualisation* and the *pars tensa* is punctured at either the 5 o'clock or 7 o'clock position (**Figure 10a–d**) in order to avoid the germinal epithelium overlying the manubrium of the malleus. Interference with the germinal epithelium of the eardrum will interfere with healing of the ruptured eardrum.

The catheter is advanced through the incised TM, directed ventrally into

the bulla and gentle suction is used to retrieve any material within the bulla. If a spinal needle was used, the stylet is withdrawn prior to suctioning. If the bulla is dry, 1 or 2 ml of normal saline can be infused into the bulla and then immediately retrieved. This material is submitted for culture and antibiotic sensitivity testing. Cytological evaluation of the material is also possible.

In the case of a suppurative otitis media, myringotomy may also serve to decrease the fluid pressure behind the eardrum. The fluid escapes into the external ear canal, which must be periodically flushed to remove this debris.

Imaging of the tympanic bulla

Radiographic assessment of the bullae can be very helpful in determining the extent of bony involvement and the degree of soft tissue filling within the bulla. However, the absence of radiographic changes in the bullae does not rule out otitis media, especially the more acute cases.

Two principle views are used. First is the rostrocaudal open mouth, with the beam directed through the mouth and pharynx, skylining the bullae (**Figure 11**). Additional views can be taken using a lateral oblique view of each bulla with the X-ray beam directed through the ramus of the mandible

(Figure 12). The former view is best for unilateral disease as it allows direct comparison between one side and the other.

In a dog with minimal bony changes, the bullae will appear as normal, thin-walled circular structures medial to the mandibular rami on the rostrocaudal view. The cortical outline will be thin and the middle of the bullae will be radiolucent, since the bullae are filled with air. On the lateral oblique view, the bony portion of the horizontal ear canal will be seen as a circular bony area with air density in the middle contained within the cortical bone of the bulla.

When the bulla is chronically affected, either the intraluminal or extraluminal bone may show new bone production or sclerosis. The cartilage of the external canal may have also calcified and may be easily seen on a radiograph (Figure 13). Often an entire bulla will appear radiopaque, since there can be large volumes of thick exudate or tissue growths filling the air space. If lytic lesions are present, there may be

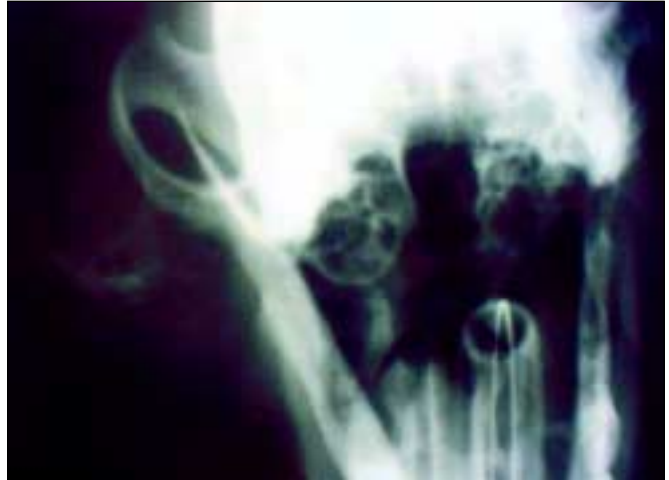

Figure 13 Rostrocaudal, open mouth view of the bullae and external ear canals of a cocker spaniel. The right ear exhibits calcification of the cartilages in the external ear canal, increased soft tissue density within the right bulla and increased bone density within the fine trabeculae of the bullae.

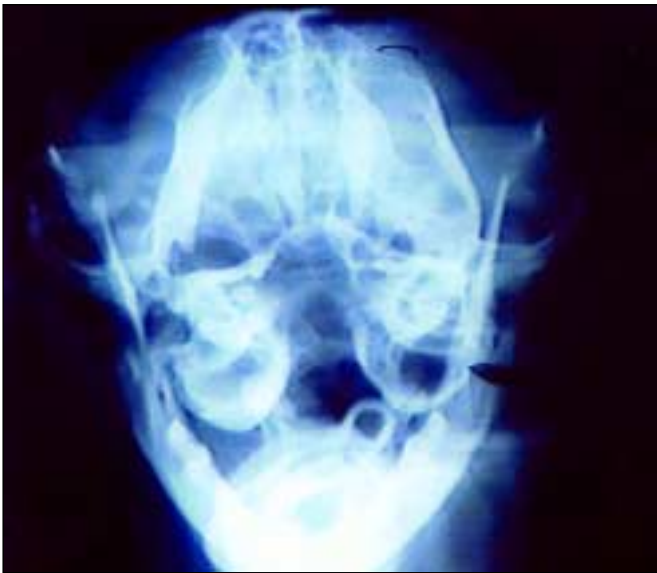

Figure 11 Rostrocaudal, open-mouth radiograph, in this case of a cat, clearly reveals the opaque nature of the right bulla.

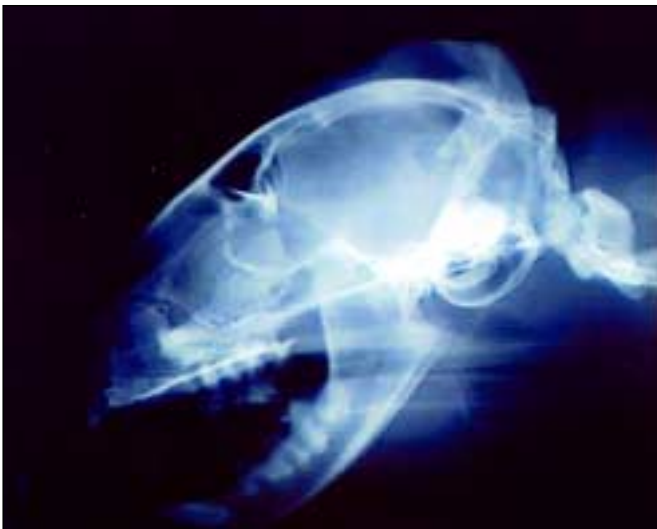

Figure 12 Lateral, partially oblique, view demonstrating the bullae, again of a cat.

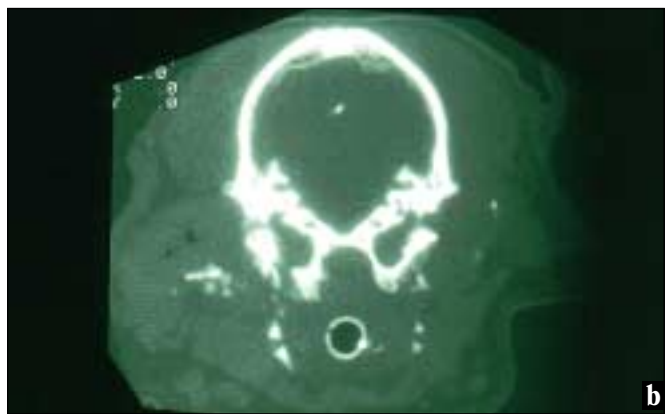
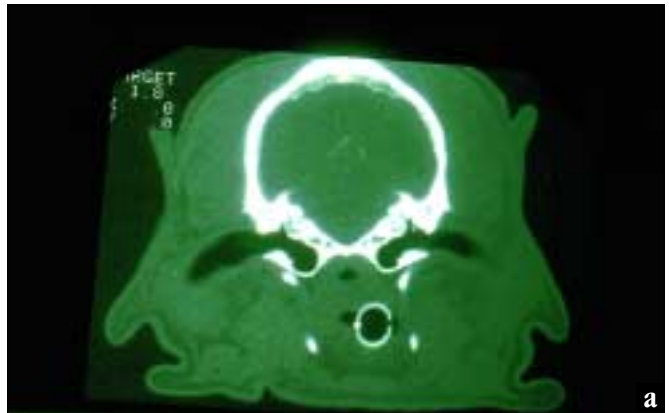


Figure 14 CT scans of: (a) a normal cocker spaniel and (b) one with chronic otitis externa and otitis media. (a) Here the air within the external ear canals is visible and the interior of the bullae is black, indicating air within. (b) Here there is stenosis of the external ear canals, and dystrophic mineralisation is present in the left external ear canal and in the TM. There is lysis of the left bulla.

CT scans courtesy Dr W. Brauner, Auburn University College of Veterinary Medicine.



radiolucent areas or the bone comprising the bulla may be absent, as in squamous cell carcinoma. Dogs with previous ventral bulla osteotomy may be identified. One or both bullae may be affected. If unilateral disease is present, a comparison between the normal and abnormal bulla makes radiographic assessment easier.

If large volumes of flushing solution are infused into the ear canal of a dog with a ruptured TM prior to radiographic assessment, a misreading of the radiograph can occur, since the bullae become filled with the flushing fluid and will appear radiopaque on the radiograph. One limitation of radiographic evaluation is that old sclerotic lesions in the bullae of aged animals (particularly in cats) cannot be differentiated from a more current proliferative otitis media lesion.

Computed axial tomography (CAT scan) of the tympanic bullae, where available, may aid in differentiating bony lesions in the bulla from soft tissue reactions. These radiographs provide views in the horizontal, vertical, and sagittal planes. CAT scans provide a number of views in these planes taken at various distance intervals, with each successive view slightly further from the previous one. Each successive view may be considered like one slice of bread removed from an entire loaf with each slice being derived from a different part of the whole.

Even when the ear canal is stenotic and otoscopic examination is impossible, CAT scans are able to give a clear impression of the status of the ear canal distal to the stenosis as well as giving clues to the pathology in the middle ear (**Figure 14a and b**). Bony lesions of the bulla can be differentiated from soft tissue lesions using CAT scans. Size of the lesion may be estimated from the distances of the successive views.

Magnetic resonance imaging (MRI) of the ear is also being investigated as a means of visualising the middle and inner ear. MRI can utilise the presence of fluids, such as the endolymph within the cochlea and semicircular canals, to provide contrast to the examinations. MRI gives better soft tissue resolution than a CAT scan.

● REFERENCES ●

1. Little, C. J. L., Lane, J. G., Pearson, G. R. Inflammatory middle ear disease of the dog: the pathology of otitis media. *Veterinary Record* 1991; **128**: 293–296.
2. Little, C. J. L., Lane, J. G. An evaluation of tympanometry, otoscopy, and palpation for assessment of the canine tympanic membrane. *Veterinary Record* 1989; **124**: 5–8.
3. Trower, N. D., Gregory, S. P., Renfrew, H., Lamb, C. R. Evaluation of the canine tympanic membrane by positive contrast canalography. *Veterinary Record* 1998; **142**: 78–81.
4. Gotthelf, L. N. Secondary otitis media: an often overlooked condition. *Canine Practice* 1995; **20**: 14–20.
5. Cole, L. K. Microbial flora and antimicrobial sensitivity patterns of isolated pathogens from the horizontal ear canal and middle ear in dogs with otitis media. *Journal of the American Veterinary Medical Association* 1998; **212**: 534–538.