

Otitis: Anatomy Every Practitioner Should Know

► **Craig E. Griffin, DVM, DACVD^a**
Animal Dermatology Clinic
San Diego, California

Chronic otitis externa is a difficult, frustrating problem. Four etiologic components must be considered: primary and secondary causes and perpetuating and predisposing factors.¹ Usually, these cases are complex and involve more than one component. Perpetuating factors are changes in the anatomy and physiology of the ear that occur in response to inflammation in the ear canal and the perpetuating factors already present. They are self-perpetuating, are not disease specific, and include failure of self-cleaning mechanisms and proliferative changes that create folds and stenosis of the lumen of the ear canal. Elimination of perpetuating factors often requires aggressive cleaning of the ear and long-term therapy. It is important to avoid damaging key structures while aggressively cleaning the ear. Therefore, to adequately diagnose and manage perpetuating factors, veterinarians must recognize normal ear anatomy and physiology.

Anatomy

The ear (auris) is the vestibulocochlear organ. It is divided into three major portions: external, middle, and inner (FIGURE 1). The external ear consists of the pinna (auricle) and ear canal (external acoustic meatus). The shape of the pinna varies widely among breeds. For the purpose of describing anatomy, this article considers the erect-eared pinna (as seen on German shepherds) as it projects dorsally and laterally, with its concave surface facing rostrally. Numerous muscle attachments allow the pinna to move and thereby improve its function of helping collect sound waves. The sound waves enter the ear as they pass through the external orifice of the ear canal, located at the base of the pinna. The ear canal, which can be 5 to 10 cm in length, travels to the tympanic membrane and middle

ear, which are enclosed by bones of the skull. Some giant-breed dogs have ear canals up to 11 cm long. More detailed descriptions of the ear canal are given elsewhere.² The tympanic membrane and medial end of the ear canal are located ventral and caudal to, but almost on the same medial-to-lateral plane as, the eye (FIGURE 2). The most important anatomic structures with regard to otitis are the external ear canal, tympanic membrane, and middle ear.

External Ear

The external ear is formed from two pieces of cartilage and a bony canal that are covered by skin. It ends medially at the thin tympanic membrane. The epithelium of the ear canal is continuous with the epithelium of the lateral aspect of the tympanic membrane so that the complete

At a Glance

- **Anatomy**
Page 504
- **Physiology**
Page 510

^aDr. Griffin discloses that he has financial relationships with Efficas, Intervet/Schering-Plough Animal Health, Novartis Animal Health, Pfizer Animal Health, Sogeval, and Teva Animal Health.

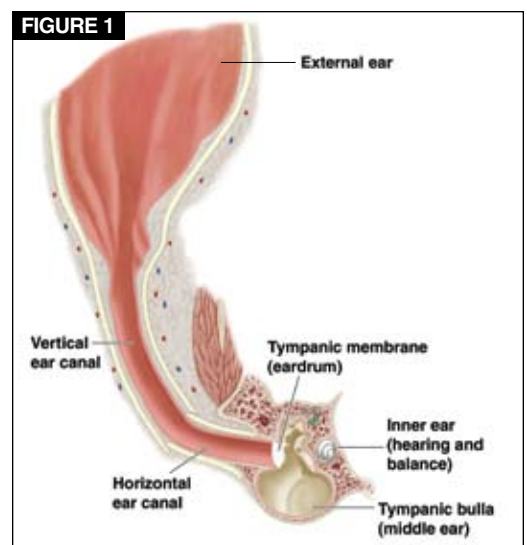


Illustration showing a cross-section of the ear and its major components. With permission from Pfizer Atlas of Infection in Dogs and Cats. Wilmington, DE: The Gloyd Group, Inc; 2008.

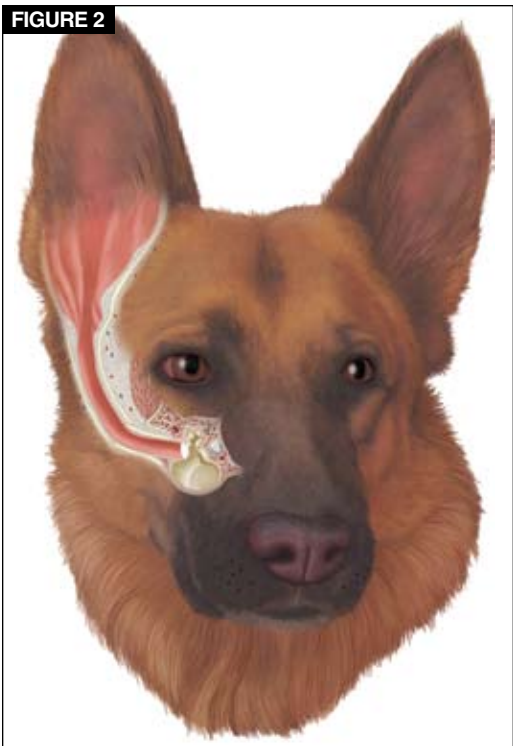FIGURE 2

Illustration of the relative locations of the ear canal and middle ear. With permission from *Pfizer Atlas of Infection in Dogs and Cats*. Wilmington, DE: The Gloyd Group, Inc; 2008.

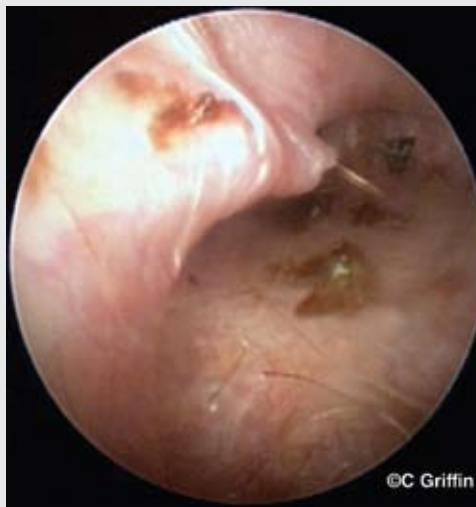ear canal is lined with epithelium. The larger portion of cartilage (the auricular cartilage) forms the pinna and most of the ear canal.

The pinna rolls onto itself at the external orifice of the external ear canal (**FIGURE 1**). From the external orifice, the canal travels ventrally and slightly rostrally. This is the vertical canal. In the vertical canal, a projection of auricular cartilage emerges from the medial surface under the skin. This projection is unnamed, and its size varies between breeds and between individuals of the same breed. However, it is recognizable when examining the ear with an otoscope because it creates a “corner” around which the examiner must proceed to gain access to the canal. To prevent the auricular projection from blocking access to the ear canal lumen during otoscopic examination, pull the pinna dorsally and laterally. The tension created partially reduces the projection and straightens the ear canal lumen, allowing better access with the otoscope (**FIGURE 3**).

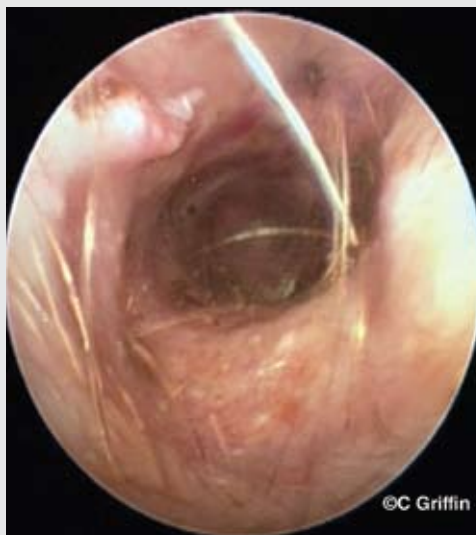At its ventral end, the ear canal bends

FIGURE 3

Straightening the pinna to perform the ear examination.^a



The auricular projection before the pinna is straightened.



View of the ear canal after the pinna has been straightened. Note the auricular projection at top left.

^aAll photographs are copyright of Craig E. Griffin.

medially and continues until it reaches the tympanic membrane. This section, from the bend to the tympanic membrane, is the horizontal ear canal. The skin of the horizontal canal is surrounded by cartilage: the auricular cartilage surrounds the lateral portion, while the smaller anular cartilage, which extends between the auricular cartilage and the external portion of the bone of the external acoustic

QuickNotes

Aggressive cleaning is often needed to manage perpetuating factors, but care must be taken to avoid damaging key anatomic structures.

VIDEO



To see an otoscopic video of a normal ear canal, visit

CompendiumVet.com.

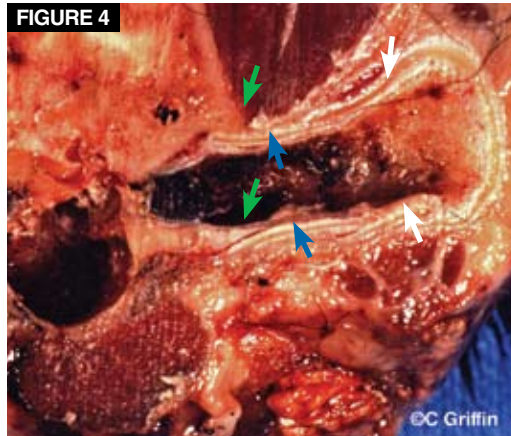


FIGURE 4
The anular cartilage (*blue arrows*) is overlapped by the distal end of the auricular cartilage (*white arrows*). Note how the anular cartilage overlaps or inserts within the bone of the external acoustic meatus (*green arrows*).

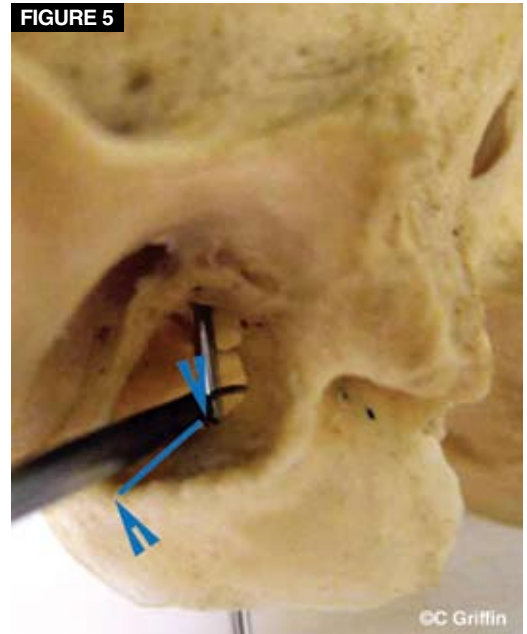


FIGURE 5
The bony external acoustic meatus of a dog skull. The *blue arrowheads* point to the ventral wall of the lateral and medial edges. The medial arrowhead is where the ventral portion of the pars tensa of the tympanic membrane would attach. The *blue line* indicates the portion of the horizontal canal where the skin would lie over bone rather than cartilage.

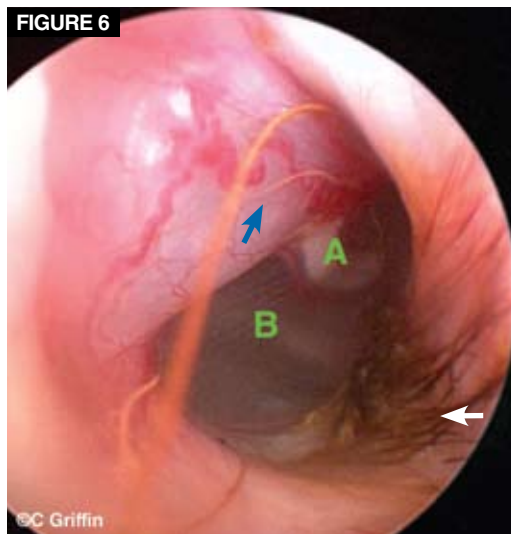



FIGURE 6
A normal canine medial horizontal canal, ending at the tympanic membrane. Note the tuft of hairs (*white arrow*) adjacent to the ventral portion of the tympanic membrane. The *blue arrow* is on a dilated, distended pars flaccida with its prominent vasculature. Note the manubrium of the malleus (*A*) and the pars tensa (*B*).

QuickNotes

When otitis is present, the skin covering the auricular projection is often inflamed. The pressure of an otoscope cone, especially the edge of the cone, may result in pain and resistance to examination.

VIDEO



To see videos of an abnormal tympanic membrane and tympanic membrane movement in response to water pressure, visit CompendiumVet.com.

meatus, surrounds the medial portion (**FIGURE 4**). The anular cartilage and bony external acoustic meatus overlap so that dorsally, the cartilage lies inside the bone of the orifice, but ventrally, the bone is inside the cartilage. The size of the bony external acoustic meatus varies; in midsize dogs, it is about 1 cm long (**FIGURE 5**). Unlike the skin lining the cartilaginous canal, the skin lining the acoustic meatus lies on bone and therefore is not subject to

movement and massage. The change from cartilage to bone can be palpated with an angled Buck curette.

The medial ring of the acoustic meatus is the location of the tympanic membrane. Often, larger primary hairs grow adjacent to the tympanic membrane (**FIGURE 6**), commonly on the ventral wall of the lumen. These hairs are a helpful landmark for locating the ventral tympanic membrane when an ear is diseased and the tympanic membrane is not readily apparent.

Tympanic Membrane

The tympanic membrane consists of internal and external epithelial surfaces enclosing a thin layer of connective tissue that includes the manubrium of the malleus. It separates the external ear from the middle ear tympanic cavity.

The tympanic membrane of the dog is made up of the pars flaccida and pars tensa (**FIGURE 7**). The pars flaccida, a small area of the dorsal to rostradorsal aspect, is relatively flaccid and quite vascular. This structure may

bulge out, can appear cystlike, and can hide the manubrium. Most of what is seen of the tympanic membrane when it is examined through an otoscope is the large pars tensa. A normal pars tensa is translucent, with striations that extend from the manubrium of the malleus out to the periphery. A whitish area with a line or ragged margin can sometimes be seen through the lower to middle section of the pars tensa. This whitish structure is best seen with a strong light source, such as a video otoscope. It represents a structure in the middle ear: the free edge of the septum bulla, which separates the tympanic cavity into dorso-lateral and ventromedial parts (FIGURE 7).

In dogs, the manubrium of the malleus is C shaped. It is located near the middle of the dorsal part of the pars tensa and points in a rostrocaudal direction. The concave aspect of the C faces rostrally, toward the nose. A perpendicular line from the top of the manubrium would point ventrally. Tension on the manubrium gives the tympanic membrane a mildly concave outer contour.² The tympanic membrane is oriented at about a 30° to 45° angle from a dorsal-to-ventral plane. This creates a pocket or groove on the ventral floor of the horizontal canal, adjacent to the tympanic membrane, where small amounts of wax can accumulate. The tympanic membrane moves in response to pressure such as that generated by flushing and cleaning the ear canal.

In cats, the tympanic membrane also consists of a pars tensa and pars flaccida, but to date, I have not observed a dilated pars flaccida in a cat. The manubrium of the malleus is relatively larger, is much straighter, and points more rostrally in cats than in dogs (FIGURE 8). In cats and dogs, when myringotomy is performed, the incision should be made in the caudal ventral quadrant of the tympanic membrane (i.e., ventral and caudal to the tip of the manubrium; FIGURE 9).

Middle Ear

The middle ear consists of the tympanic cavity and the medial wall of the tympanic membrane; the auditory ossicles and their associated ligaments, muscles, and nerves; and the auditory (eustachian) tube. Normally, the only communication from the middle ear cavity to the outside environment is through the auditory tube, which opens into the nasopharynx and

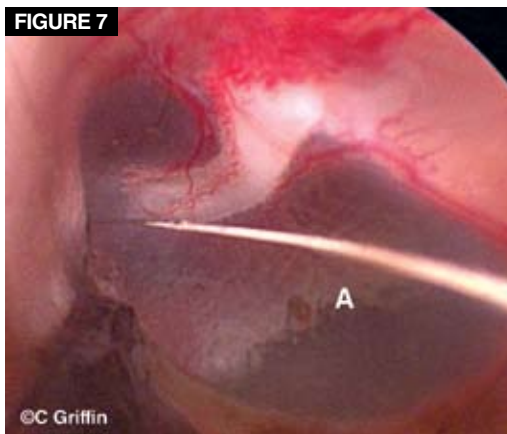


FIGURE 7
Normal left tympanic membrane with the pars tensa and the vascular pars flaccida. Vessels extend down along the manubrium of the malleus. Note the shadow of the septum bulla (A) seen behind the pars tensa.

serves to equalize pressure on either side of the tympanic membrane.

The tympanic cavity may be divided clinically into three parts: dorsal, middle, and ventral. The dorsal part, also called the *epitympanic recess*, is the smallest and contains the head of the malleus and its articulation with the incus. The middle part, or *tympanic cavity proper*, is adjacent to the tympanic membrane rostrally and laterally. The prominent structure on the caudal medial aspect of the tympanic cavity proper is the promontory of the petrosal part of the temporal bone (FIGURE 10). The barrel-shaped promontory is situated roughly opposite to the mid-dorsal aspect of the tympanic membrane. At the caudal end of the promontory is the cochlear window, which communicates with the cochlea of the bony labyrinth (FIGURE 11). This structure must be avoided when a myringotomy is performed and the middle ear is flushed. The caudal opening of the auditory tube lies in the rostral-medial part of the middle tympanic cavity. The middle portion of the tympanic cavity communicates freely with the ventral portion, contained in the egg-shaped tympanic bulla. The ventral portion is the largest portion of the tympanic cavity.

A ridge of bone, the septum bulla, projects from the medial wall of the tympanic bulla into the cavity between its middle and ventral components. The septum bulla is readily seen just ventral and caudal to the promontory and cochlear window (FIGURE 12) and

QuickNotes

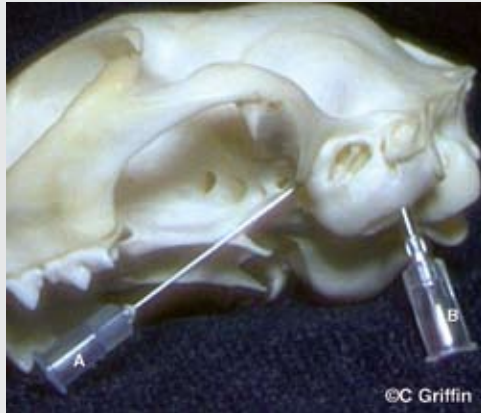In an abnormal ear, tympanic movement is helpful in identifying the tympanic membrane.

VIDEO

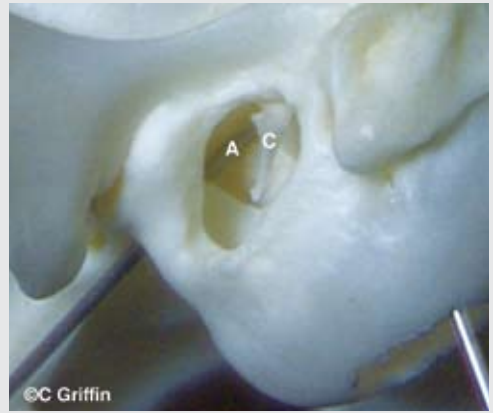
To see a video of the tympanic cavity in a cat skull, visit CompendiumVet.com.

FIGURE 8

Anatomy of the feline middle ear.



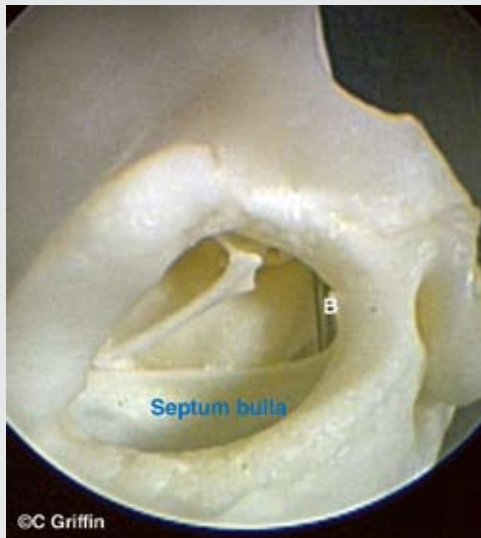
Needle A is inserted into the auditory tube. Needle B goes into the tympanic cavity up through a ventral bulla osteotomy opening.



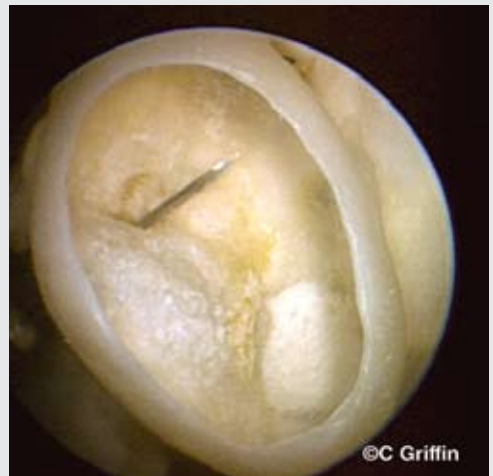The needle (A) can be seen in the middle ear. Note that the manubrium (C) is relatively larger than that in the canine ear, and the long axis points rostroventrally, not ventrally as in dogs.

QuickNotes

When possible, the middle ear anatomy of cats should be avoided when cleaning.



The needle (B) is inserted through the auditory tube. This view is through the external acoustic meatus.



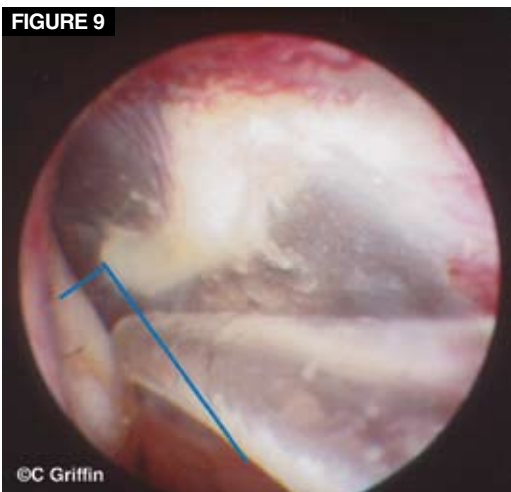
The needle is pointing from the dorsal portion of the ventral bulla into the ventral portion. Fluid that reaches the ventral portion is trapped by the septum. This ventral-to-dorsal view looks through a hole in the ventral bulla.

often has many bony ossicles or “knobbed spicules” along the free edge in the tympanic cavity² (FIGURE 13). This ridge makes passing catheters or tubes into the ventral bulla very difficult. When the middle ear is flushed, the goal is to direct fluid pressure below the septum bulla. The inner ring of the osseous external acoustic meatus is a helpful landmark because it is the attachment site of the tympanic membrane. If the ventral inner edge can be palpated with an ear loop, then the tympanic membrane is either ruptured or out of

its normal anatomic position (FIGURE 14). Once the ventral medial edge of the osseous external acoustic meatus is reached, the cochlear window is a short distance (5 to 8 mm) medially. Care should be taken to stay caudal and ventral to the cochlear window.

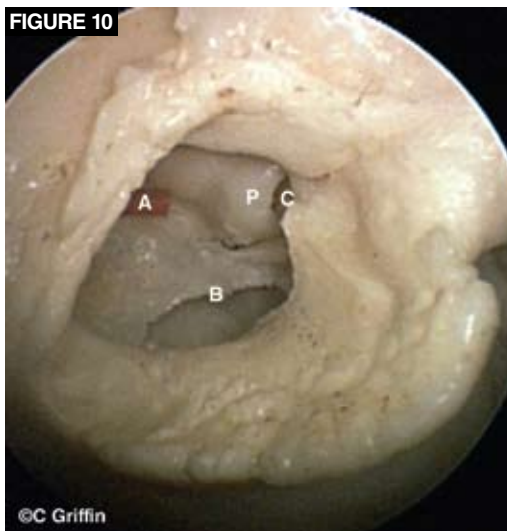
The middle ear in cats is very different from that in dogs in that the septum bullae is very large and nearly divides the ventral portion of the tympanic cavity into a small dorsolateral and a large ventromedial part—the pars tympanica and pars endotympanica, respectively. These

FIGURE 9



A tomcat catheter in the left external ear canal, pointing to the optimal site for performing a myringotomy. The incision is made in the caudal ventral quadrant of the pars tensa of the tympanic membrane (*blue lines*). This site is caudal to the convex surface and below the tip of the manubrium.

FIGURE 10



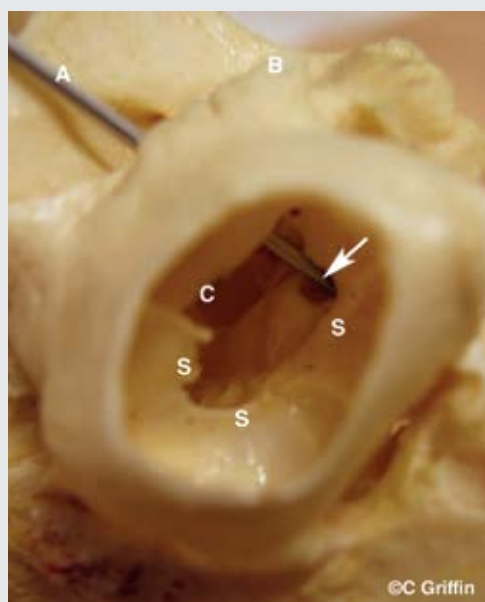
View through the left external acoustic meatus of a dog skull. An orange feeding tube (A) enters the middle ear from the auditory tube. The septum bulla (B), promontory (P), and opening in the promontory to the cochlear window (C) can be seen.

FIGURE 11

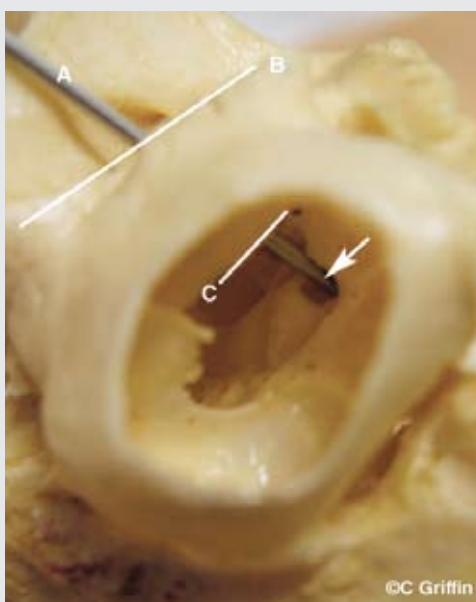
Ventral to dorsal view through an opening in the ventral wall of the bulla of a dog skull. Note the metal rod (A) passing through the lateral margin of the bony external acoustic meatus (B). C indicates the medial edge of the bony external acoustic meatus. The tip of the metal rod (*arrow*) is through the cochlear window. This site must not be touched or subjected to direct pressure during procedures such as flushing the middle ear.

QuickNotes

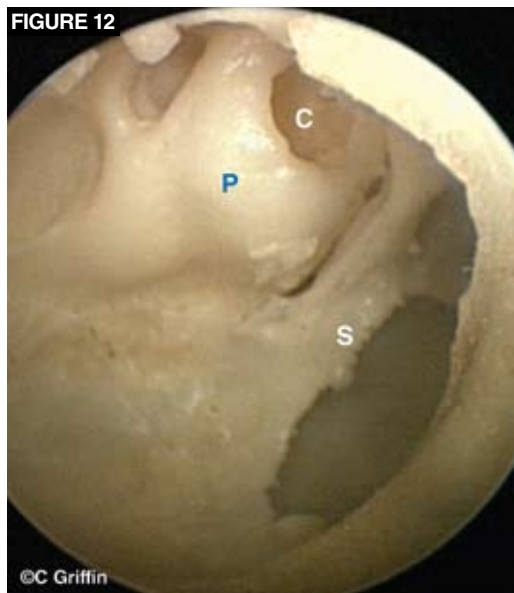When the tympanic membrane is ruptured, ear medications and cleansers should be used cautiously and be nonototoxic.



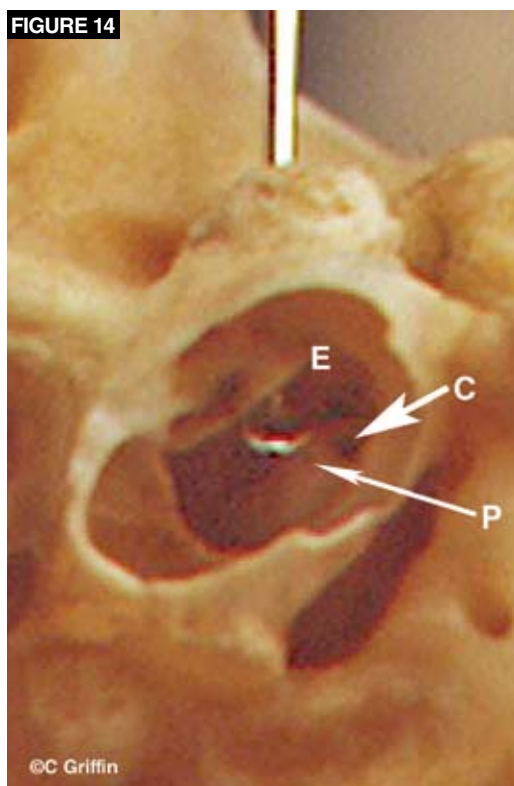
S indicates the septum bulla.



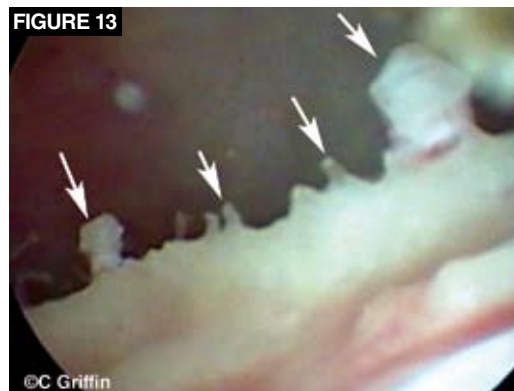The white lines indicate the lateral ventral edge and medial ventral edge of the bony external acoustic meatus. The distance between the lines varies from 7 to 15 mm and is narrower on the rostral side.



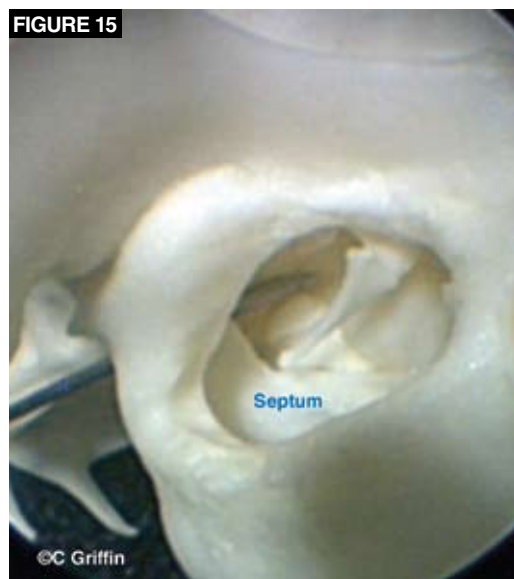
View of the middle ear through the external acoustic meatus. P = promontory, S = septum bulla, C = cochlear window.



View of the left middle ear from the ventral bulla, with an ear loop just over the medial ventral edge of the external acoustic meatus (E). If the tip of the ear loop drops over this edge, it has passed the normal attachment site of the ventral edge of the pars tensa on the tympanic ring. Note the promontory (P) and the cochlear window (C).



Close-up view of the septum bulla showing the bony ossicles (arrows) on the free margin.



Feline skull showing a needle going through the auditory tube into the tympanic cavity proper. The large, almost complete septum is seen ventral to the manubrium of the malleus.

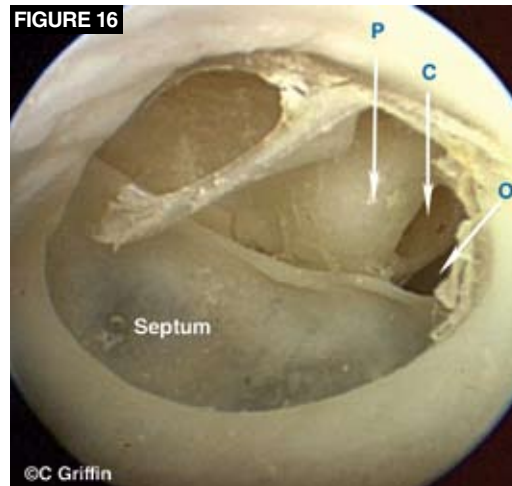
two parts of the tympanic cavity communicate through a small opening in the caudal medial quadrant near the promontory and cochlear window (FIGURES 15 AND 16). Liquid medications instilled into the feline tympanic cavity are difficult to remove because they are trapped once they enter the ventromedial portion.

Physiology

The skin lining the ear canal is relatively smooth. Similar to the skin in most body regions, it has a thin epidermis and a dermis that contains adnexa (hair follicles and sebaceous and apocrine glands). The vertical canal has relatively more

adnexa than the horizontal canal. To date, breed differences in the number of sebaceous glands have not been shown, although apocrine gland and hair follicle densities differ.³ The skin and adnexa constantly produce exfoliating corneocytes, intercellular material, and glandular secretions. This material forms cerumen (earwax), which is thought to play a protective role. IgA, IgG, and IgM have been identified in canine cerumen.⁴ IgG is the predominant immunoglobulin in both normal and inflamed ears. Its relative concentration increases significantly in the presence of disease. Cerumen also contains a wide variety of lipids, which may have some antimicrobial effects⁵; however, bacteria and yeast are present in normal ears.

Cerumen is constantly being produced throughout the ear canal, and if it were to build up, blockage could result. However, there is a normal clearing mechanism: the movement of the epidermis. Epithelial migration, in which the surface of the skin lining the ear canal constantly moves from the tympanic membrane laterally to the external orifice of the ear canal (**FIGURE 17**),

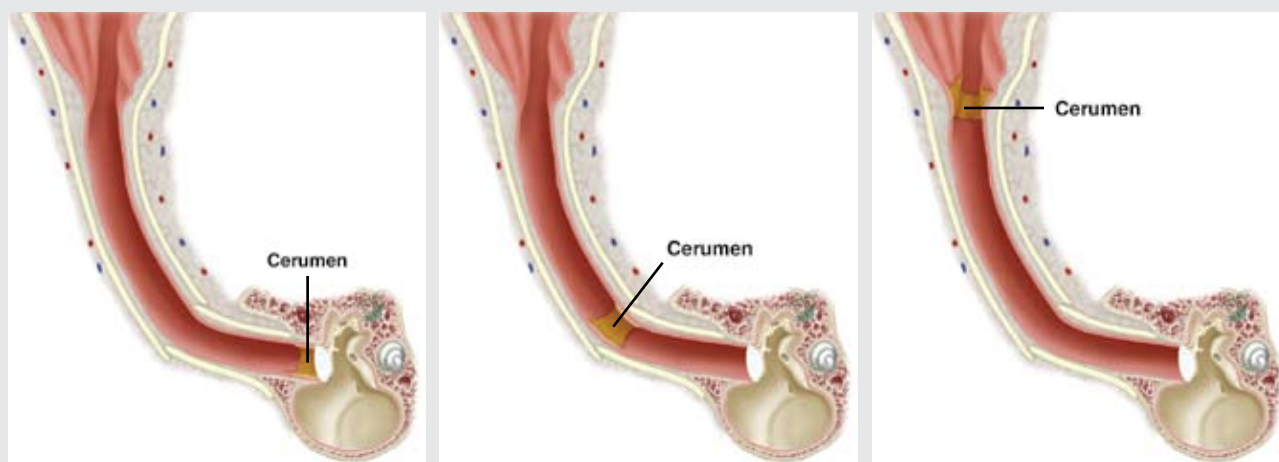


Close-up photo of a feline middle ear viewed through the external acoustic meatus. Note the opening (O) in the septum that communicates with the larger ventromedial part of the tympanic cavity, the endotympanic part of the temporal bone. C = cochlear window, P = promontory.

has been shown in humans and guinea pigs.⁶ It seems likely that besides removing the cerumen, this process also facilitates the removal of sur-

FIGURE 17

Illustrations depicting the migration of cerumen and surface epithelial cells from the deep ear canal to the external orifice.



This process must function for an ear canal to remain healthy. With permission from Pfizer Atlas of Infection in Dogs and Cats. Wilmington, DE: The Gloyd Group, Inc; 2008.

face microorganisms and even small particulate debris trapped in the sticky cerumen.

Cytologic studies of normal ear cerumen have produced variable results in numbers of bacteria and yeast but have found essentially no inflammatory cells.^{7,8} These studies evaluated samples at 400× dry field magnification, not by oil immersion (1000×), which is my preferred magnification. It has been stated that 400× magnification is not sufficient to identify all bacteria.⁹ Based on a published, non-peer-reviewed evaluation of cerumen from normal

dog and cat ears at 1000× magnification,¹ I consider bacteria excessive when more than five cocci or one rod per 1000× (oil immersion) field is found. Normal numbers of yeast are even more controversial, although I consider more than three organisms in dogs or more than one in cats per oil immersion field to be increased. Rarely, up to 20 organisms per 1000× field can be normal for an individual dog or cat. However, these numbers are irrelevant once multiple inflammatory cells are present, as this finding is abnormal. **C**

References

1. Scott DW, Miller WH Jr, Griffin CE. *Muller and Kirk's Small Animal Dermatology*. 6th ed. Philadelphia: WB Saunders; 2001.
2. Evans H. *Miller's Anatomy of the Dog*. 3rd ed. Philadelphia: WB Saunders; 1993.
3. Stout-Graham M, Kainer RA, Whaler LR, Macy DW. Morphologic measurements of the external horizontal ear canal of dogs. *Am J Vet Res* 1990;51(7):990-994.
4. Huang HP, Little CJ, Fixter LM. Effects of fatty acids on the growth and composition of *Malassezia pachydermatis* and their relevance to canine otitis externa. *Res Vet Sci* 1993;55(1):119-123.
5. Huang HP, Fixter LM, Little CJ. Lipid content of cerumen from normal dogs and otitic canine ears. *Vet Rec* 1994;134(15):380-381.
6. Johnson A, Hawke M. An ink impregnation study of the migratory skin in the external auditory canal of the guinea-pig. *Acta Otolaryngol* 1986;101(3-4):269-277.
7. Ginel PJ, Lucena R, Rodriguez JC, Ortega J. A semiquantitative cytological evaluation of normal and pathological samples from the external ear canal of dogs and cats. *Vet Derm* 2002;13(3):151-156.
8. Tater K, Scott DW, Miller WH Jr, Erb HN. The cytology of the external ear canal in the normal dog and cat. *J Vet Med* 2003;50:370-374.
9. Angus JC. Otic cytology in health and disease. *Vet Clin North Am Small Anim Pract* 2004;34(2):411-424.



Your gateway to trusted resources for your veterinary team.

vetlearn
.com

- ▶ Web exclusives
- ▶ Articles
- ▶ News
- ▶ Videos
- ▶ VLS online store
- ▶ Product Spotlight