

Review

# Neurological complications in renal failure: a review

R. Brouns<sup>a,b</sup>, P.P. De Deyn<sup>a,b,\*</sup>

<sup>a</sup> Department of Neurology and Memory Clinic, Middelheim General Hospital, Antwerp, Belgium

<sup>b</sup> Laboratory of Neurochemistry and Behaviour, Born-Bunge Foundation, University of Antwerp, Universiteitsplein 1, B-2610 Antwerp, Belgium

Received 3 February 2004; received in revised form 27 July 2004; accepted 27 July 2004

## Abstract

Neurological complications whether due to the uremic state or its treatment, contribute largely to the morbidity and mortality in patients with renal failure. Despite continuous therapeutic advances, many neurological complications of uremia, like uremic encephalopathy, atherosclerosis, neuropathy and myopathy fail to fully respond to dialysis. Moreover, dialytic therapy or kidney transplantation may even induce neurological complications. Dialysis can directly or indirectly be associated with dialysis dementia, dysequilibrium syndrome, aggravation of atherosclerosis, cerebrovascular accidents due to ultrafiltration-related arterial hypotension, hypertensive encephalopathy, Wernicke's encephalopathy, hemorrhagic stroke, subdural hematoma, osmotic myelinolysis, opportunistic infections, intracranial hypertension and mononeuropathy. Renal transplantation itself can give rise to acute femoral neuropathy, rejection encephalopathy and neuropathy in graft versus host disease. The use of immunosuppressive drugs after renal transplantation can cause encephalopathy, movement disorders, opportunistic infections, neoplasms, myopathy and progression of atherosclerosis. We address the clinical, pathophysiological and therapeutical aspects of both central and peripheral nervous system complications in uremia.

© 2004 Elsevier B.V. All rights reserved.

**Keywords:** Renal failure; Uremia; Dialysis; Renal transplantation; Encephalopathy; Neuropathy; Myopathy

## Contents

1. Introduction .....	2
2. Central nervous system complications .....	2
2.1. Encephalopathy .....	2
2.2. Dementia .....	6
2.3. Cerebrovascular disease .....	6
2.4. Osmotic myelinolysis .....	7
2.5. Movement disorders and restless legs syndrome .....	8
2.6. Opportunistic infections .....	8
2.7. Neoplasms .....	9
2.8. Intracranial hypotension .....	9
2.9. Intracranial hypertension .....	9
3. Peripheral nervous system complications .....	9
3.1. Mononeuropathy .....	9
3.2. Polyneuropathy .....	10
3.3. Myopathy .....	11
4. Conclusion .....	11
References .....	11

\* Corresponding author. Fax: +32 3 8202618.

E-mail address: peter.dedeyn@ua.ac.be (P.P. De Deyn).

## 1. Introduction

Patients with renal failure often have signs and symptoms related to fluid and electrolyte disturbances, anemia, malnutrition, bone disease and gastrointestinal problems. Vascular and neurologic impairment in particular remain an important source of morbidity and mortality in this vulnerable patient population.

In this paper, disease related and treatment related neurological complications in renal failure will be reviewed. With the introduction of dialysis and renal transplantation, the spectrum of neurological complications changed. The incidence and severity of uremic encephalopathy, atherosclerosis, neuropathy and myopathy have declined but many patients fail to fully respond to dialytic therapy.

Moreover, dialytic therapy or kidney transplantation may even induce neurological complications. Dialysis dementia, dialysis dysequilibrium syndrome, hypertensive encephalopathy and cerebrovascular accident due to ultrafiltration-related arterial hypotension can occur as a direct consequence of dialysis. Furthermore, dialysis is associated with aggravation of atherosclerosis and can contribute to the development of Wernicke's encephalopathy, hemorrhagic stroke, subdural hematoma, osmotic myelinolysis, opportunistic infections, intracranial hypertension and neuropathy. Patients with renal failure may benefit from

kidney transplantation, but the use of immunosuppressive drugs can cause encephalopathy, movement disorders, opportunistic infections, neoplasms, myopathy and progression of atherosclerosis. Renal transplantation itself can give rise to acute femoral neuropathy, rejection encephalopathy and neuropathy in graft versus host disease (Table 1). In what follows, we will address both central and peripheral nervous system complications in patients with renal failure.

## 2. Central nervous system complications

### 2.1. Encephalopathy

In patients with renal failure, encephalopathy is a common problem that may be caused by uremia, thiamine deficiency, dialysis, transplant rejection, hypertension, fluid and electrolyte disturbances or drug toxicity [1] (Table 2). In general, encephalopathy presents with a symptom complex progressing from mild sensorial clouding to delirium and coma. It is often associated with headache, visual abnormalities, tremor, asterix, multifocal myoclonus, chorea and seizures. These signs fluctuate from day to day or sometimes from hour to hour [2].

Uremic encephalopathy may accompany acute or chronic renal failure, but in patients with acute renal failure the

Table 1  
Neurological complications related to treatment of renal failure

Neurological complication	Pathophysiology
Wernicke's encephalopathy	Accelerated loss of thiamine in hemodialysis
Dialysis dementia	Aluminium-containing dialysate Aluminium-based phosphate binders
Rejection encephalopathy	Cytokine production in renal transplant rejection
Dysequilibrium syndrome	Reverse urea effect in dialysis Intracellular acidosis in cerebral cortex
Immunosuppressiva-associated encephalopathy	Disruption blood–brain barrier, axonal swelling, extracellular edema, demyelination, drug metabolites, microvascular damage
Ischemic stroke	↑ Atherosclerosis due to unsuitable dialysate calcium concentration, bioincompatibility in dialysis, calcium-containing phosphate binders, immunosuppressive
Multi-infarct dementia	Intradialytic hypotension
Hypertensive encephalopathy	Cerebral vasogenic edema due to (intradialytic) hypertension
Intracerebral hemorrhage	Anticoagulation in hemodialysis
Subdural hematoma	Anticoagulation in hemodialysis, rapid ultrafiltration, use of hypertonic dialysate
Osmotic myelinolysis	Rapid correction of chronic hypo- or hyperosmolar state, eventually by dialysis
Movement disorders	Drug-induced in hemodialysis patients Immunosuppressive agents (cyclosporine, tacrolimus)
Opportunistic infections	↑ Infection hazard and immunosuppression in dialysis immunosuppressiva in renal transplant patients
Neoplasms	Immunosuppression due to dialysis immunosuppressiva in transplant patients
Intracranial hypertension	Pseudotumor cerebri secondary to dialysis or steroids
Carpal tunnel syndrome	Compression median nerve by arteriovenous fistula or dialysis-associated amyloidosis
Acute femoral neuropathy	Compression or ischemia during renal transplantation
Non-uremic neuropathy	Graft vs. host disease in transplant patients
Steroid-induced myopathy	Use of steroids, especially in transplant patients

Table 2  
Encephalopathy in renal failure

Encephalopathy	(Presumed) pathophysiology	Therapeutic or preventive measures
Uremic encephalopathy	Accumulation neurotoxins Disturbance intermediary metabolism Hormonal disturbances	Dialysis or kidney transplantation
Wernicke's encephalopathy	Thiamine deficiency	Thiamine administration
Dialysis encephalopathy/dementia	Aluminium accumulation	Use of aluminium free dialysate Avoid aluminium-based phosphate binders Administration of deferoxamine
Rejection encephalopathy	Cytokine production due to rejection process	↑ Immunosuppression
Hypertensive encephalopathy	Cerebral vasogenic edema	Antihypertensive treatment
Dysequilibrium syndrome	Reverse urea effect Intracellular acidosis in cerebral cortex	Self-limited
Fluid and electrolyte disturbances	↑ Calcium, magnesium, natrium, osmolality ↓ Natrium, osmolality	Correction of electrolyte imbalance
Drug toxicity	Drugs metabolised or excreted by kidney Immunosuppressive drugs	Dose reduction or cessation

symptoms are generally more pronounced and progress more rapidly [2,3]. Besides the general symptom complex of encephalopathy, focal motor signs and the “uremic twitch-convulsive” syndrome can be seen [2,4]. Even in patients with neurologically asymptomatic chronic renal disease, impaired cognitive processing can be disclosed by event-related potentials. Increase in P3 latency and decrease in P3 amplitude is found. After hemodialysis, significant improvement occurs, but the level of azotemia correlates poorly with the

degree of neurological dysfunction [3]. Electroencephalographic findings in uremic encephalopathy are non-specific but correlate with clinical symptoms and therefore may be of diagnostic value especially if serial studies are performed. Typically, generalised slowing with an excess of delta and theta waves and sometimes bilateral spike-wave complexes are found (Fig. 1). With progression of the uremic state, the electroencephalogram becomes slower [2,3]. Cerebral imaging is not necessary for the diagnosis, but is useful to ex-

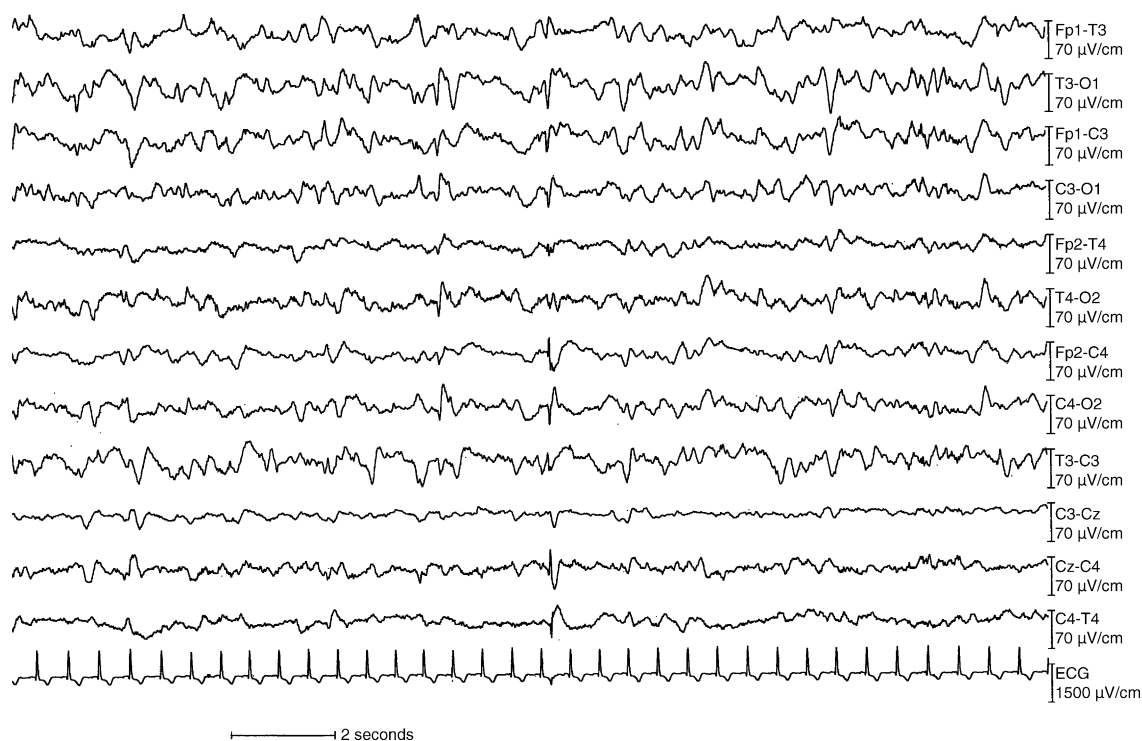


Fig. 1. Electroencephalographic findings in a patient with uremic encephalopathy, showing generalised slowing with an excess of delta and theta waves and bilateral spikes.

clude other causes of confusion. The pathophysiology of uremic encephalopathy is complex and poorly understood. Accumulation of metabolites, hormonal disturbance, disturbance of the intermediary metabolism and imbalance in excitatory and inhibitory neurotransmitters have been identified as contributing factors. Renal failure results in accumulation of numerous organic substances that possibly act as uremic neurotoxins, but no single metabolite has been identified as the sole cause of uremia [5]. Symptoms are usually alleviated by dialysis or successful renal transplantation. Accumulation of urea, guanidino compounds, uric acid, hippuric acid, various amino acids, polypeptides, polyamines, phenols and conjugates of phenol, phenolic and indolic acids, acetone, glucuronic acid, carnitine, myo-inositol, sulphates, phosphates and “middle molecules” has been reported in the literature [6,7]. Among the guanidino compounds, guanidinosuccinic acid, methylguanidine, guanidine and creatinine were found to be highly increased in serum, cerebrospinal fluid and brain of uremic patients [8]. It is postulated that these compounds may contribute to the epileptic and cognitive symptoms accompanying uremic encephalopathy [9–11]. Activation of the excitatory *N*-methyl-D-aspartate receptors and concomitant inhibition of inhibitory GABA<sub>(A)</sub>-ergic neurotransmission have been proposed as underlying mechanisms [8]. Moreover, guanidinosuccinic acid possibly inhibits transketolase, a thiamine-dependent enzyme of the pentose phosphate pathway that is important for the maintenance of myelin. Inhibition of transketolase could cause demyelinating changes contributing to both central and peripheral nervous system changes in chronic uremia. Animal studies and *in vitro* testing demonstrated disturbances of the intermediary metabolism with increased levels of creatine phosphate, adenosine triphosphate and glucose, and decreased levels of monophosphate, adenosine diphosphate and lactate. These changes are associated with a decrease in both brain metabolic rate and cerebral oxygen consumption and are consistent with a generalized decrease in brain energy use. Moreover, inhibition of cerebral sodium-potassium-ATPase was shown in experimental uremic animals [3]. This could correlate with the elevation of intracellular sodium and could therefore be associated with some of the aspects of cerebral dysfunction, particularly seizure activity. Hormonal disturbances have also been suggested to play a role in the pathogenesis of uremic encephalopathy. Blood levels of parathyroid hormone, insulin, growth hormone, glucagon, thyrotropin, prolactin, luteinizing hormone and gastrin are elevated in patients with uremia. In particular, the pathophysiological role of parathyroid hormone has been examined. The mechanisms by which parathyroid hormone can produce central nervous system effects even in the absence of renal failure, are not completely understood. However, the increased calcium content in diverse tissues, among which brain, in patients with uremia and secondary hyperparathyroidism suggests that parathyroid hormone may somehow facilitate the entry of calcium in these tissues [3]. Since calcium is an essential mediator of neurotransmitter release and

plays a major role in intracellular metabolic and enzymatic processes, alterations in brain calcium may possibly disrupt cerebral function by interfering with any of these processes.

Wernicke's encephalopathy typically presents with the triad of ophthalmoplegia, ataxia and cognitive symptoms or disturbances of consciousness. Because this triad is rarely present and because of similarities with uremic encephalopathy, this disorder often remains unrecognized with high fatality as a consequence. A good outcome however, can be obtained if thiamine is administered immediately [12]. Wernicke's encephalopathy in uremic patients is rare, but especially hemodialysis patients are at risk because not only low thiamine intake but probably also accelerated loss of thiamine [3,13].

Dialysis encephalopathy or dialysis dementia is a subacute, progressive and often fatal disease that presents with dysarthria, dysphasia, apraxia, personality changes, psychosis, myoclonus, seizures and finally dementia [4,14]. In most cases, it progresses to death in 6 months. Errors in dialysis water purification or the use of aluminium-containing dialysate and aluminium-based phosphate binders to treat hyperphosphatemia causes accumulation of this element in many organs, inducing microcytic anemia, osteomalacia and dialysis encephalopathy [15–18]. Chelation with deferoxamine is the treatment of choice [2,19]. Dialysis encephalopathy is rare nowadays, but sporadic cases due to the use of aluminium hydroxide occur [3].

Rejection encephalopathy presents with headache, confusion or convulsions in a patient with systemic features of acute graft rejection [20]. Over 80% of cases occurs within 3 months of transplantation, but cases up to 2 years after transplantation have been reported. The overall prognosis is good, with rapid and complete recovery after treatment of the rejection episode [21]. Electroencephalography, neuroimaging and lumbar puncture do not contribute to the diagnosis. Pathophysiologically, cytokine production secondary to the rejection process may be important.

In hypertensive encephalopathy, patients display the encephalopathic symptom complex in combination with severe hypertension. Magnetic resonance imaging often demonstrates posterior leukoencephalopathy (Fig. 2). Accurate diagnosis and immediate antihypertensive treatment is regarded as a medical emergency since symptoms and imaging abnormalities may be reversible [22]. Hypertensive encephalopathy is thought to be caused by vasogenic edema predominantly in the posterior areas of the brain due to impaired cerebrovascular autoregulation, endothelial injury and elevated plasma concentrations of natriuretic peptides. Recombinant human erythropoietin for correction of renal anemia is known to cause hypertension in about 35% of the patients. Hypertensive encephalopathy is estimated to occur in 5% [23–25]. This complication is unrelated to the extent or rate of increase in hematocrit, but is associated with a rapid increase in bloodpressure even in previously normotensive patients. Monitoring of blood pressure, gradually increasing doses of recombinant erythropoietin and administration of

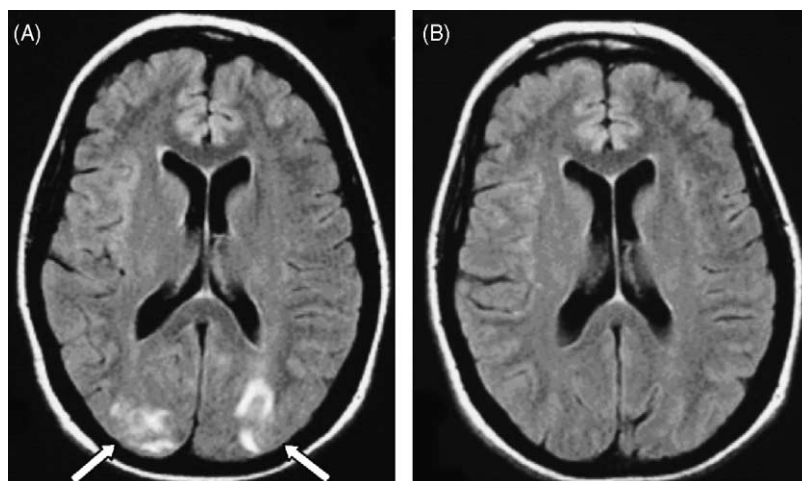


Fig. 2. Initial MRI study in a patient with severe hypertension, headache, confusion and visual disturbances reveals typical subcortical edema in the occipital regions with only minimal cortical involvement (arrows) on axial FLAIR sequence (A). One week later, after antihypertensive treatment and clinical improvement, follow-up MRI study reveals complete resolution of the lesions on FLAIR images (B).

conventional antihypertensive therapy, often prevent this complication [26,27]. However, if hypertension persists, recombinant erythropoietin should be reduced in dose or temporarily discontinued [26].

Dialytic treatment can be associated with the dialysis dysequilibrium syndrome which typically presents clinically with headache, nausea, muscle cramps and twitching, delirium and seizures [28]. The dysequilibrium syndrome tends to be self-limiting and subsides over several hours to days [3]. In literature, controversy concerning the pathogenesis of this condition exists. The “reverse urea hypothesis” suggests that during hemodialysis, urea is cleared more slowly from brain than from blood causing an osmotic gradient that leads to net flow of water into the brain resulting in transient cerebral edema [29,30,31]. Other studies however, demonstrated that urea is cleared from brain and blood at the same rate [32]. The “idiogenic osmole hypothesis” proposes that an osmotic gradient between brain and plasma develops during rapid dialysis because of newly formed brain osmoles, identified as amino acids, polyols and trimethylamines [29,33]. An alternative hypothesis suggests that the cerebral edema is caused by intracellular acidosis in the cerebral cortex due to increased production of organic acids [3,4]. Slow dialysis and addition of osmotically active solute to the dialysate can prevent the condition [3].

Fluid and electrolyte disturbances are common in patients with renal failure and can produce central nervous system depression with encephalopathy as the major clinical manifestation. Especially hypercalcemia, hypermagnesemia, hypo- and hypernatremia, hypo- and hyperosmolality are known to cause this problem [34,35]. Symptoms subside after correction of the electrolyte imbalance.

Encephalopathy due to drug toxicity is often seen in patients with kidney failure and mainly occurs with drugs that are normally metabolised or excreted by the kidney

like isoniazide, encainide, pseudoephedrine, metronidazole, vigabatrin, acyclovir, radiographic contrast and cefazolin [36–43]. Further, it has been demonstrated that protein binding of several drugs (phenytoin, theophylline, diazepam, prazosin, imipramine, propranolol, cimetidine, clonidine and methotrexate) can be altered in chronic renal failure, which not only might affect the therapeutic effectiveness of these drugs, but also could result in neurotoxicity [44]. Immunosuppressant-associated encephalopathy has been described with the calcineurin inhibitors cyclosporine [45] and tacrolimus (FK506) [46] and to a lesser extent with muromonab-CD3 (OKT3) [47]. Neurotoxicity associated with these drugs is more frequent when toxic levels accumulate in the body but may even be apparent at levels within therapeutic range. Common manifestations are tremor, headache, cerebellar or extrapyramidal signs [48–50]. The most serious complication is reversible posterior leukoencephalopathy [46] with subcortical and deep white matter changes [22,51,52] resembling upon imaging to those found in hypertensive encephalopathy. Cerebral cortex involvement and contrast enhancement have occasionally been noted [53]. Recognition of immunosuppressant-associated encephalopathy is important, since dose reduction or discontinuation of immunosuppressive drugs mostly results in resolution of clinical symptoms and neuroimaging abnormalities. The etiology of neurotoxicity associated with cyclosporin and tacrolimus is not fully understood and probably multifactorial [53]. Disruption of the blood–brain barrier, which could facilitate the passage of substances into the cerebral interstitium, causing axonal swelling and extracellular edema has been postulated. But also demyelination has been described. This may be the result of inflammatory or ischemic phenomena, the latter possibly due to loss of local vascular regulation or direct vascular toxicity. Other hypotheses include production of active drug metabolites or microvascular damage due to endothe-

lial damage with the release of vasoactive peptides [54] and thrombotic microangiopathy.

Clinically, it is difficult to differentiate encephalopathy from non-convulsive status epilepticus, which may occur in end stage renal disease. However, differentiation is important and can mostly be achieved by electroencephalography. Clinical or electroencephalographic improvement after administration of anticonvulsant agents suggests an epileptic etiology [55].

## 2.2. Dementia

Dementia is more common in patients with renal failure than in the general population. The incidence of dementia in aged patients undergoing dialysis is estimated at 4.2% [56], with predominant occurrence of multi-infarct dementia [57,58]. The incidence of multi-infarct dementia in this group is estimated at 3.7% [56], which is 7.4 times more frequent than in the general elderly population. This can be explained by the unfavourable cerebrovascular risk profile in these patients.

Dementia should be differentiated from delirium and depression, which are also common problems in renal failure. Subacute and fast progressive dementia can occur in progressive multifocal leukoencephalopathy and dialysis dementia.

Cerebral atrophy is common in patients with chronic renal failure, even in patients without evident cognitive, affective or behavioural changes [59–61]. However, on psychometric testing, there is often evidence of intellectual deficits. The atrophy might be caused by endogenous uremic toxins, arterial hypertension or cerebral hypoperfusion due to atherosclerosis [62–64].

## 2.3. Cerebrovascular disease

Cerebrovascular disease is a predominant cause of morbidity and mortality in patients with chronic renal failure. This population is prone to the development of atherosclerosis and ischemic stroke. But the presence of several risk factors also predisposes to hemorrhagic complications.

Ischemic stroke in renal failure mainly results from atherosclerosis, thromboembolic disease or intradialytic hypotension.

Atherosclerosis in patients with chronic renal failure is generally more diffuse and distally located than in the general population, probably because of combination of traditional atherogenic risk factors such as male gender, age, diabetes mellitus, hypertension, dyslipidemia and smoking with factors more specifically related to renal failure and its treatment [65–67]. In particular, renal failure is or may be associated with accumulation of guanidino compounds, oxidative and carbonyl stress, hyperhomocysteinemia and disturbances of the calcium-phosphate metabolism [68–72].

Accumulation of endogenous guanidino compounds in chronic renal failure may play an important role in endothelial dysfunction. Especially, the L-arginine ana-

logues  $N^G$ - $N^G$ -asymmetrical dimethylarginine (ADMA) and  $N^G$ -monomethyl-L-arginine (L-NMMA) can competitively inhibit the synthesis of nitric oxide, that mediates the vasodilator effects of endothelium-derived relaxing factor and consequently plays a role in determining vasomotor tone in several vascular beds, including the cerebral circulation [68,70,73]. Furthermore, recent research suggests that the guanidino compound guanidinosuccinic acid might potentiate the deleterious effects of cerebral hypoxia under uremic conditions [74]. Therefore, guanidino compounds should be considered as possible uremic toxins that may play a significant role in the cerebrovascular and neurological disorders observed in uremia [70]. Elevated plasma S-nitrosothiol levels in hemodialysis patients have been reported and a protective role against nitrosative stress in uremia is suggested [75]. However, recently a lack of S-nitrosothiol bioavailability has been described, which could contribute to the high cardiovascular risk of patients with chronic renal failure [76].

Oxidative and carbonyl stress in chronic renal failure are associated with the inflammatory state that plays a role in atherogenesis [77]. Besides oxidation of low-density lipoproteins [78,79], elevated levels of advanced glycation end products (AGEs) have been described in patients with renal failure. This phenomenon has been attributed to impaired renal clearance of AGEs, in combination with increased endogenous formation and dietary intake [80]. Therapeutic strategies to reduce AGEs may involve dialysis technique and inhibition of AGE formation. Daily hemodialysis, online hemodiafiltration, the use of ultrapure dialysate and peritoneal dialysate free of reactive carbonyl compounds are useful measures [81,82]. Inhibition of AGE formation can be achieved by angiotensin converting enzyme inhibitors, angiotensin receptor blockers or aminoguanidine [81].

Large observational studies established that hyperhomocysteinemia is an independent risk factor for atherosclerosis [83]. The prevalence of hyperhomocysteinemia in patients with chronic renal failure is estimated to be 85–100%, but the cause is obscure [71,84,85]. Therapeutic intervention with high dosage folic acid and oral Vitamin B or L-5-methyltetrahydrofolate can reduce homocysteine levels in this patient population [86,87] but without evidence of improvement of endothelial function [88,89]. Unfortunately, most hemodialysis and renal transplant patients are partially refractory to this treatment regimen [90]. Enhanced dialysis over super-flux membranes is a more efficient strategy to reduce homocysteine levels. This is probably the result of improved removal of uremic toxins with inhibitory activities against homocysteine-metabolizing enzymes, rather than better dialytic clearance of homocysteine itself [91–94]. Homocysteine levels also decrease after renal transplant, but tend to remain higher than normal [71].

Soft tissue calcification, with an increased risk of vascular calcification, arterial stiffness and worsening of atherosclerosis can also occur due to disturbances of the calcium metabolism [95]. Secondary hyperparathyroidism due to

reduced active Vitamin D production by the kidneys and phosphate retention, can lead to tertiary hyperparathyroidism. Vitamin D supplementation is important in prevention and management of secondary hyperparathyroidism. Hyperphosphatemia is usually treated by means of intestinal phosphate binders. Calcium-containing phosphate binders can aggravate vascular calcification, particularly if taken together with Vitamin D analogues and a high calcium dialysate concentration. Therefore, new calcium- and aluminium-free phosphate binders and a suitable dialysate calcium concentration can be useful, especially in patients with metastatic calcification and/or hypercalcemic episodes. Surgical parathyroidectomy is the ultimate means of treating hypercalcemic hyperparathyroidism, when medical therapy has failed.

Treatment of renal failure can have a detrimental effect on atherosclerosis. Dialysis by itself appears to promote the development of arterial disease, maybe due to bio-incompatibility or oxidative stress [78]. Furthermore, progression of atherosclerosis may be influenced by the use of immunosuppressive agents used in renal transplant recipients [65]. Many studies suggest that immune mechanisms are involved in the development of atherosclerotic plaques, which harbour a significant proportion of activated T lymphocytes [96].

Thromboembolic ischemic CVA may result from either characteristic cardiac disease in chronic renal failure, e.g. dilated cardiomyopathy and arrhythmias [97,98] or “artery-to-artery embolism” due to severe atherosclerosis.

Ultrafiltration-related arterial hypotension is a common complication of hemodialysis, especially in older patients with anemia [99]. Autonomic neuropathy also plays an important role [100]. Severe arterial hypotension can result in cerebral hypoperfusion and eventually ischemic stroke which is typically located in the boundary zones between the vascular territories of the anterior and middle cerebral artery or between the middle and the posterior cerebral artery [101]. Treatment consists of infusion with saline [102]. The use of sodium profiling, cool dialysate, midodrine and possibly sertraline can increase hemodynamic stability during dialysis [103,104].

Since renal anemia is an independent risk factor for stroke and cardiovascular events in chronic renal failure [105,106], treatment with recombinant human erythropoietin seems an important preventive measure.

Hemorrhagic stroke may include intracerebral, subarachnoid or subdural hemorrhage. The uremic state causes platelet dysfunction and altered platelet–vessel wall interaction resulting in a bleeding tendency [107]. This is partially corrected by effective dialysis, but hemodialysis by itself is associated with a higher incidence of intracerebral hemorrhage (8.7 to 10.3 per 1000 patient years, relative risk compared to normals 10.7) and subarachnoid hemorrhage (0.8 per 1000 patient years, relative risk compared to normals 4.0) [66,108,109]. Furthermore, prognosis of hemorrhagic stroke in patients with chronic renal failure is poor

with high morbidity and mortality up to 60% [66,110–112].

The predestination of patients renal failure for intracerebral and subarachnoid hemorrhage is multifactorial. Hypertension, polycystic kidney disease and the use of anticoagulation or platelet antiaggregants are the most important risk factors [109,111,113,114]. The mutations in the PKD-1 or -2 gene in patients with autosomal dominant polycystic kidney disease account for an 10-fold increased risk for development of cerebral vascular malformations, i.e. saccular aneurysms and dolichoectasia. There is a tendency for these malformations to cluster in families and to rupture more frequently and earlier, mostly resulting in subarachnoid hemorrhage [3,115–118]. The use of heparin during hemodialysis and coumarins or platelet antiaggregants in the prevention of fistula thrombosis probably further elevates the risk of hemorrhagic stroke [111,112,114]. Hemodialytic strategies to reduce bleeding risk include the use of regional or minimal heparinisation. Dialytic modalities that completely preclude systemic anticoagulation, i.e. peritoneal dialysis or heparin-free dialysis are mostly indicated for patients who are actively bleeding or recently suffered from a cerebral hemorrhage [111,119].

Systemic anticoagulation in hemodialysis can also be complicated by acute and chronic subdural hematoma. Other predisposing factors are hypertension, head trauma, rapid ultrafiltration and the use of hypertonic dialysate [120]. The occurrence of subdural hematoma is well known but frequently overlooked because of clinical similarity with encephalopathy and dementia. However, diagnosis can easily be made by cerebral imaging. Neurosurgical intervention, if necessary, can be done by burr hole aspiration or craniotomy. However, conservative therapy with replacement of hemodialysis by peritoneal dialysis or continuation of hemodialysis without anticoagulation is often sufficient [121–123].

#### 2.4. Osmotic myelinolysis

Osmotic myelinolysis in patients with renal failure mainly occurs within the central basis pontis, but extrapontine regions including the midbrain, thalamus, basal nuclei and cerebellum can be affected as well. Central pontine myelinolysis is clinically characterized by acute progressive quadriplegia, dysarthria, dysphagia and alterations of consciousness. With expansion of the demyelination through the midbrain, horizontal and vertical gaze paralysis can be seen. Parkinsonism or ataxia can occur when respectively the basal nuclei or the cerebellum are affected.

On magnetic resonance imaging (MRI), T2-weighted images demonstrate hyperintense patchy areas of demyelination [124]. The prognosis is often fatal and in those who survive, maximum recovery may require several months. Treatment is supportive only. In view of the hypothetical pathogenesis, it probably is important to correct chronic hyponatremia slowly and to avoid hypernatremia.

The exact pathogenetic mechanisms leading to osmotic myelinolysis are still unclear. It is postulated that glial cell edema, which is caused by fluctuating osmotic forces, results in compression of fiber tracts and induces demyelination and eventually cell death. Cellular edema can be precipitated by aggressive correction of a chronic hypo- or hyperosmolar state [125]. Osmotic myelinolysis after rapid correction of prolonged hyponatremia—or less frequent hypernatremia—by dialysis is a known problem [126]. On the other hand, rapid serum sodium correction by hemodialysis occurs often, but only few patients develop demyelination.

### 2.5. Movement disorders and restless legs syndrome

Movement disorders in patients with renal failure can occur as a result of encephalopathy, medication or structural lesions.

Several types of involuntary movements can occur in metabolic encephalopathy. Asterix or “flapping tremor” is probably caused by sudden loss of tonus, originating from cortical dysfunction and clinically consists of multifocal action-induced jerks that can even mimic drop attacks in severe cases [127,128]. In myoclonus, the patient exhibits shock-like contractions of a muscle or a group of muscles. These contractions are irregular in rhythm and amplitude and are followed by relaxation. In uremia, both spontaneous action myoclonus and stimulus-sensitive myoclonus with good response to benzodiazepines can occur [129]. It has been suggested that uremic myoclonus is caused by a disturbance of function in the lower brainstem reticular formation due to water–electrolyte imbalance leading to microcirculatory and degenerative changes [130]. A typical movement disorder in uremic encephalopathy is the uremic “twitch-convulsive” syndrome that consists of intense asterix and myoclonic jerks that are accompanied by fasciculations, muscle twitches and seizures [2,4]. Finally, thiamine deficiency is thought to cause a dysfunction of the basal ganglia which may induce chorea [131].

Drug-induced involuntary movements in patients with chronic renal failure are more frequently seen in patients after kidney transplantation. Neurotoxic effects of immunosuppressive agents like cyclosporine and tacrolimus may manifest as tremor or other extrapyramidal signs [50].

Secondary to cerebrovascular disease, extrapontine myelinolysis, intracerebral neoplasms and opportunistic infections, patients with chronic renal failure are prone to development of structural lesions, which can be located in the basal ganglia and thus induce extrapyramidal movement disorders. Furthermore, acute movement disorders can be caused by bilateral basal ganglia lesions due to hypoperfusion with global brain ischemia and selective vulnerability of the basal ganglia to hypoxemia and uremic toxins [132].

The restless legs syndrome is a common and incapacitating disorder that is characterized by an imperative need to move the legs because of paresthesias that worsen during periods of inactivity. As a consequence, patients suf-

fer from severe sleep disturbances. At least 20% of patients with chronic renal failure suffer from this incapacitating disorder [133,134]. In general, dialysis does not substantially improve uremic restless legs syndrome, but cool dialysate fluid (36.5 °C) has been linked to some relieve [135]. Treatment with levodopa, dopamine agonists, benzodiazepines, gabapentin, clonidine or opioids may bring relief [136–139]. Substantial improvement of restless legs symptoms after kidney transplantation has been described [140]. The etiology is uncertain, but the association with peripheral neuropathy and chronic renal failure is well known.

### 2.6. Opportunistic infections

Since the usual signs of infection in immunosuppressed patients are blunted and since infection with uncommon and atypical opportunistic organisms often occurs, early diagnosis may be difficult. Treatment with antimicrobial therapy and decrease of immunosuppressive agents should not be delayed. Neurological infections in patients with renal failure mainly present as acute, subacute or chronic meningitis, encephalitis, myelitis or brain abscess [141,142]. Opportunistic bacterial infections include pathogens as *Nocardia asteroides*, *Mycobacterium tuberculosis* and *Listeria monocytogenes* [143]. Fungi are often represented by *Cryptococcus neoformans*, *Aspergillus fumigatus*, *Candida*, *Pneumocystis carinii*, *Histoplasma*, *Mucor* and *Paracoccidioides* species [144]. Reactivation of latent viral infection with herpes simplex, cytomegalovirus and JC Polyomavirus are not uncommon [145,146]. Infection with cytomegalovirus is the most frequent opportunistic infection following renal transplantation. It is usually asymptomatic, but invasive forms with meningitis, encephalitis, myelitis and involvement of nerve roots can develop. Reactivation of the JC Polyomavirus and infection of oligodendrocytes results in progressive multifocal leukoencephalopathy [146]. Clinical manifestations include severe and rapid progressive dementia, ataxia, visual disturbances and other focal neurologic deficits, generally progressing to a vegetative state within 6 months. Unfortunately, all therapeutic regimens are still in experimental phase. Metazoan and protozoan infections with *Strongyloides stercoralis* and *Treponema cruzi* respectively, have been described [147].

Lumbar puncture is often needed for diagnosis, but should only be performed after exclusion of intracranial space occupying lesions by neuroimaging. If a definitive diagnosis cannot be made in reasonable time, empirical therapy must be started [3].

Naturally, immunosuppression is the main cause of opportunistic infections. The uremic state itself is associated with a defective phagocytic function of polymorphonuclear white blood cells, leading to an immunodeficiency especially against bacterial infection [148]. This problem is even more prominent in patients with dialysis or renal transplants. Dialysis patients also have a increased hazard of infection, especially fistula and shunt infections [149] and transplant pa-



tients suffer from a severe suppression of cell-mediated immunity, due to use of immunosuppressant agents.

### 2.7. Neoplasms

The immunosuppressive state of patients with renal failure not only predisposes to infection with opportunistic pathogens, but is also associated with an increased incidence of de novo neoplasia [145,150]. Although development of neoplasms in the neurologic system is rare, malignant meningioma [151] and primary central nervous system lymphoma have been described in end stage renal failure [152–155]. Immunosuppressive therapy after renal transplantation is associated with an increased risk of lymphoproliferative disease. The majority of post-transplantation lymphoproliferative disorders (PTLD) are of B-cell origin and contain Epstein–Barr virus [156]. This condition is estimated to occur in 1–2% of renal transplantation patients and generally has a poor clinical outcome [157,158]. With alteration in immunosuppression regimens, the localisation of PTLD have changed over time. Central nervous system involvement was the predominant site of disease prior to the use of cyclosporine [159]. With the institution of cyclosporine, thoracic, and abdominal presentations became more common. Standard therapy for PTLD is not well established. Often, immunosuppression is reduced or even ceased, which is associated with an increased risk of allograft rejection [160]. Radiotherapy is often applied for locations in the central nervous system [161]. Acyclovir, surgical excision, several combinations of chemotherapeutic agents and monoclonal antilymphoma immunotherapy have been reported to be useful, often in combined therapy [157,160].

With the increased incidence of urogenital, gastrointestinal, hematologic and endocrine neoplasia in end stage renal disease [150,162], one can expect a higher risk of brain metastasis.

### 2.8. Intracranial hypotension

Orthostatic headache, occasionally associated with neck stiffness, nausea, visual disturbances, dizziness, hearing loss or abducens nerve palsy strongly suggests intracranial hypotension due to reduction of cerebrospinal fluid pressure [163–165]. Accurate diagnosis is important since subdural hematoma may develop [163,166] and conservative management with bed rest, increased fluid intake and administration of steroids is quite effective [165]. MRI of the head typically shows diffuse pachymeningeal gadolinium enhancement, often with imaging evidence of descent of the brain [167,168]. On radioisotope cisternography, absence of activity over the cerebral convexities, even at 24 or 48 h is seen and sometimes the level of the leak can be revealed [164]. Diagnosis can be confirmed by measuring cerebrospinal fluid pressure [165]. This condition may occur spontaneously [163], secondary to cerebrospinal fluid leakage or more rarely in dehydration and uremia.

### 2.9. Intracranial hypertension

Intracranial hypertension in patients with chronic renal failure can be idiopathic or secondary to dialysis, use of steroids, or intracranial lesion (neoplasm, infection, cerebrovascular disease) [169].

The diagnostic criteria of idiopathic intracranial hypertension or pseudotumor cerebri include symptoms due to elevated intracranial pressure, normal findings on neuroimaging studies, excluding non-specific findings of raised intracranial pressure and increased cerebrospinal fluid pressure with a normal composition [170]. Clinically, intracranial hypertension manifests with headache, transient visual obscurations, and diplopia due to unilateral or bilateral sixth nerve palsy. Non-specific symptoms may include dizziness, nausea, vomiting, and tinnitus. The increase in intracranial pressure is transmitted to the structures within the intracranial cavity, including the optic nerves resulting in papilledema and progressive optic atrophy with accompanying constriction of the visual field, loss of colour vision and eventually blindness. The treatment goal is to prevent visual impairment by managing the increased intracranial pressure by management of the underlying renal disease and if possible use of acetazolamide, furosemide or corticosteroids [169,171]. Optic nerve sheath fenestration or lumboperitoneal, ventriculoperitoneal or ventriculoatrial shunting procedure should be considered in patients with deterioration of visual function despite maximum medical treatment [169].

## 3. Peripheral nervous system complications

### 3.1. Mononeuropathy

In uremia, susceptibility of the peripheral nerves to compression and local ischemia is increased. In practice especially the ulnar, median and femoral nerves are affected (Table 3).

Damage to the ulnar nerve can occur by uremic tumoral calcinosis at the wrist, in Guyon's canal [172]. Depending on the site of compression in the canal, this may cause purely motor dysfunction with paresis of intrinsic hand muscles, sensory loss to the hypothenar eminence, the small finger and the lateral part of the ring finger or mixed symptomatology. Electromyography and nerve conduction studies are useful to confirm the area of entrapment and to document the extent of the pathology. If conservative treatment with anti-inflammatory medication, tricyclic antidepressants, anticonvulsants and splinting show no response or if motor deficits develop, surgical neurolysis is indicated.

The carpal tunnel syndrome is far more common and is caused by entrapment of the median nerve in the carpal tunnel, which is formed by the flexor retinaculum and the carpal bones. Symptoms include burning pain and paresthesias involving the ventral surface of the hand and fingers I–III and medial surface of finger IV. Thenar muscle atrophy may oc-

Table 3  
Neuropathy in renal failure

Neuropathy	(Presumed) pathophysiology	Therapeutic or preventive measures
<b>Mononeuropathy</b>		
Ulnar nerve	Ischemia	Anti-inflammatory drugs
	Entrapment in Guyon's canal due to uremic tumoral calcinosis	Tricyclic antidepressants
Median nerve	Ischemia	Anticonvulsants Surgical decompression
	Entrapment in carpal tunnel due to dialysis-associated amyloidosis, uremic tumoral calcinosis, arteriovenous fistula	Local injection of corticosteroids Optimal dialysis technique Surgical decompression Renal transplantation
	Ischemia	Mostly spontaneous recovery
Femoral nerve	Peroperative compression	Mostly spontaneous recovery
<b>Polyneuropathy</b>		
Uremic	Dialyzable neurotoxins	Vitamin supplements (biotin, pyridoxine, cobalamin, thiamine)
		Tricyclic antidepressants Anticonvulsants Dialysis Renal transplantation
Non-uremic	Graft vs. host disease Systemic vasculitis Diabetic polyneuropathy	Specific treatment for underlying disease

cur. Renal transplantation relieves the symptoms but does not reverse the amyloidosis [173]. The alteration of dialysis strategy with the use of high permeable, biocompatible membranes and pure dialysis water has a role in the prevention of disease and slows down its progression [174]. In the case of developed lesions, local injection of corticosteroids and timely surgical decompression can be required, but carpal tunnel syndrome caused by chronic renal failure has relatively limited postoperative improvement and high recurrence rate when compared with the idiopathic carpal tunnel syndrome [175]. Besides the increased susceptibility to pressure palsies, uremic patients are prone to compression of the median nerve in the carpal tunnel secondary to dialysis-associated amyloidosis [176–178], uremic tumoral calcinosis [179] or placement of an arteriovenous shunt for dialysis. Arteriovenous shunting may increase venous pressure in the distal limb leading to nerve compression or it may result in ischemia of the median nerve due to stealing of blood from the distal limb [2,180].

In acute femoral neuropathy, patients complain of weakness in the thigh and pain or sensory deficit on the thigh and inner calf [181]. It is a known complication of renal transplantation due to peroperative compression of the nerve by

retractors or due to nerve ischemia [182]. The incidence is estimated at about 2% and most patients have an excellent chance of recovery [183].

### 3.2. Polyneuropathy

Uremic polyneuropathy occurs in approximately 60% of patients with chronic renal failure and can affect motor, sensory, autonomic and cranial nerves [2,184,185]. The condition has an unexplained male predominance [184] and clinically presents with symmetrical distal sensory loss for all modalities, which is more pronounced in the lower extremities [2]. Mostly, the adverse effects on the peripheral nervous system are minimal as long as the glomerular filtration rate exceeds roughly 12 mL/min. At glomerular filtration rates below this value, nerve conduction studies become abnormal and patients begin to demonstrate clinical signs of peripheral nerve dysfunction when about 6 mL/min is reached [185]. An early finding is elevation of the vibratory threshold and impaired temperature sensibility [186,187]. Paradoxical heat sensation, paresthesias or pain are common [188]. Later in the course, ascending hypesthesia to pinprick or touch, areflexia, restless legs, muscle weakness, cramps and atrophy can be found. The neuropathy usually evolves over several months but rarely an acute or subacute course is seen [2,185]. Pruritus is often present in renal failure, especially during dialysis [188]. Its pathogenesis is not completely understood. Autonomic neuropathy can play a role in the pathogenesis of intradialytic and orthostatic hypotension [100,189], incontinence, diarrhea, constipation, esophageal dysfunction, hyperhidrosis and impotence [2,4,184]. Cardiovascular autonomic testing should include Tilt-table test and measurement of the beat-to-beat variation in heart rate in the supine position, during deep breathing and Valsalva [190–193]. Besides parasympathetic vagal dysfunction [194,195], neuropathy of other cranial nerves, especially optic [196], trigeminal, facial [197] and vestibulocochlear [198] neuropathy have been described anecdotally [2,199]. Electrophysiologically, mainly axonal loss and secondary demyelination can be found. The most sensitive parameters in the diagnosis of uremic neuropathy are F-wave parameters from the lower limbs, vibration detection thresholds on the foot, the sural nerve sensory action potential amplitude and decreased nerve conduction velocity [185,200]. The vibratory threshold on the foot correlates with the clinical grading of neuropathy. The nerves from the upper extremities on the side of the fistula should not be used in the diagnosis due to numerous mild local nerve lesions [200]. In most patients, uremic neuropathy will stabilize or even improve during chronic dialysis [185,201–203]. Paresthesia may improve rapidly once hemodialysis is started, but other symptoms mostly persist. Progression of symptoms despite regular dialysis has been found especially after 10 years and in the elderly, but might be less pronounced when dialysis is performed with biocompatible membranes [204]. Renal transplantation can result in recovery from uremic

neuropathy through remyelination [205,206]. If extended axonal degeneration has developed and large numbers of axons are lost, results of renal transplantation are disappointing [184,185,207]. Improvement after supplementation with biotin, pyridoxine, cobalamin and thiamine has been described, possibly due to stimulation of nerve metabolism and encouragement of regeneration [208,209]. Subcutaneous erythropoietin therapy has been reported to improve motor polyneuropathy in uremic patients, especially non-diabetic individuals. The improvement may reflect remyelination, possibly through direct action of erythropoietin on the peripheral neuronal cells [210]. Symptomatic therapy with tricyclic antidepressants and anticonvulsants can be employed. The factors involved in the development of uremic polyneuropathy remain partly unknown. Since increase of nerve conduction velocities after single dialysis has been described, detoxification, e.g. removal of dialyzable neurotoxins may be important (Table 3) [4,211].

It is important to consider the possibility of non-uremic neuropathy in chronic renal failure patients, like neuropathy with graft versus host disease [212], systemic vasculitides and diabetic polyneuropathy (Table 3) [214].

### 3.3. Myopathy

Although uremic myopathy is a common finding in patients with end-stage renal disease, some confusion exists about the definition. Usually, this term is used to refer to the constellation of functional and occasionally structural muscle abnormalities in patients with chronic renal failure as a consequence of the uremic state itself [213]. Uremic myopathy usually appears in patients with a glomerular filtration rate under 25 mL/min and the progression parallels the decline of renal function [213]. The overall prevalence is estimated at 50% in dialysis patients. It manifests as proximal limb weakness, with muscle wasting, limited endurance, exercise limitation and rapid fatigability [214]. In general, physical examination, electromyography and muscle enzymes are normal [213]. Muscle biopsy occasionally reveals structural alterations, mainly fiber atrophy that predominantly involves type-II fibers [215,216]. Development of cardiomyopathy can be associated with uremic myopathy. Since no specific treatment exists for uremic myopathy, prevention with high-quality dialysis therapy is important, probably best with high-flux membranes. Furthermore, aerobic exercise training, prevention and treatment of secondary hyperparathyroidism, dietary corrections and treatment of renal anemia with recombinant human erythropoietin may be essential [213,214,217,218]. Conflicting results about L-carnitine supplementation are reported in literature. Substantial improvement after supplementation can occur in subgroups of dialysis patients [219]. Successful renal transplantation significantly reduces complaints within 2 months, but does not fully restore physical working capacity [213]. Pathogenetic mechanisms that have been proposed are a decreased clearance of uremic toxins, abnormalities in Vitamin D metabolism, insulin resistance,

carnitine deficiency and malnutrition especially with protein deficiency [220,221]. Other hypotheses include anemia, alterations in mitochondrial metabolism and abnormal oxygen conductance from the microcirculation to mitochondria, possibly due to reduced capillary/fiber ratio and widening of the capillary basement membrane [213].

Uremic myopathy should be differentiated from steroid-induced myopathy and ischemic myopathy secondary to atherosclerosis [220]. Moreover, water and electrolyte disturbances with hypermagnesemia, hypo- or hypercalcemia and hypo- or hyperkalemia in particular [35,117], can mimic myopathy.

## 4. Conclusion

Neurological complications whether due to the uremic state or its treatment, contribute largely to the morbidity and mortality in patients with renal failure. Despite continuous therapeutic progress, most neurological complications of uremia fail to fully respond to dialysis and many are elicited or aggravated by dialysis or renal transplantation.

In order to assure optimal care for patients with renal failure, both neurologists and nephrologists should be familiar with the neurologic complications that almost invariably will occur in these patients. Interdisciplinary collaboration plays an important role in prevention and/or early diagnosis and adequate treatment.

## References

- [1] Mahoney CA, Arief AI. Uremic encephalopathies: clinical, biochemical, and experimental features. *Am J Kidney Dis* 1982;2(3):324–36.
- [2] Aminoff MJ. In: Raskin NH, editor. *Neurology and general medicine*. Philadelphia: Churchill Livingstone; 1995. p. 303–19.
- [3] Burn DJ, Bates D. Neurology and the kidney. *J Neurol Neurosurg Psychiatry* 1998;65(6):810–21.
- [4] De Deyn PP, Saxena VK, Abts H, Borggreve F, D'Hooge R, Marescau B, et al. Clinical and pathophysiological aspects of neurological complications in renal failure. *Acta Neurol Belg* 1992;92(4):191–206.
- [5] Vanholder R, De Smet R, Glorieux G, Argiles A, Bourmeister U, Brunet P, et al., European Uremic Toxin Work Group. Review on uremic toxins: classification, concentration, and interindividual variability. *Kidney Int* 2003;63(5):1934–43.
- [6] Enomoto A, Takeda M, Taki K, Takayama F, Noshiro R, Niwa T, et al. Interactions of human organic anion as well as cation transporters with indoxyl sulfate. *Eur J Pharmacol* 2003;466:13–20.
- [7] Topczewska-Bruns J, Pawlak D, Chabielska E, Tankiewicz A, Buczek W. Increased levels of 3-hydroxykynurenine in different brain regions of rats with chronic renal insufficiency. *Brain Res Bull* 2002;58(4):423–8.
- [8] De Deyn PP, D'Hooge R, Van Bogaert PP, Marescau B. Endogenous guanidino compounds as uremic neurotoxins. *Kidney Int Suppl* 2001;78:S77–83.
- [9] Pan JC, Pei YQ, An L, Lai L, D'Hooge R, De Deyn PP. Epileptiform activity and hippocampal damage produced by intrahip-

- pocampal injection of guanidinosuccinic acid in rat. *Neurosci Lett* 1996;209(2):121–4.
- [10] D'Hooge R, Pei YQ, Manil J, De Deyn PP. The uremic guanidino compound guanidinosuccinic acid induces behavioral convulsions and concomitant epileptiform electrocorticographic discharges in mice. *Brain Res* 1992;598(1/2):316–20.
- [11] D'Hooge R, Pei YQ, Marescau B, De Deyn PP. Convulsive action and toxicity of uremic guanidino compounds: behavioral assessment and relation to brain concentration in adult mice. *J Neurol Sci* 1992;112(1/2):96–105.
- [12] Hung SC, Hung SH, Tarng DC, Yang WC, Chen TW, Huang TP. Thiamine deficiency and unexplained encephalopathy in hemodialysis and peritoneal dialysis patients. *Am J Kidney Dis* 2001;38(5):941–7.
- [13] Ihara M, Ito T, Yanagihara C, Nishimura Y. Wernicke's encephalopathy associated with hemodialysis: report of two cases and review of the literature. *Clin Neurol Neurosurg* 1999;101(2):118–21.
- [14] Dunea G. Dialysis dementia: an epidemic that came and went. *ASAIO J* 2001;47(3):192–4.
- [15] Berend K, van der Voet G, Boer WH. Acute aluminum encephalopathy in a dialysis center caused by a cement mortar water distribution pipe. *Kidney Int* 2001;59(2):746–53.
- [16] McKinney TD, Basinger M, Dawson E, Jones MM. Serum aluminum levels in dialysis dementia. *Nephron* 1982;32(1):53–6.
- [17] Kerr DN, Ward MK, Ellis HA, Simpson W, Parkinson IS. Aluminium intoxication in renal disease. *Ciba Found Symp* 1992;169:123–35.
- [18] Mach JR, Korchik WP, Mahowald MW. Dialysis dementia. *Clin Geriatr Med* 1988;4(4):853–67.
- [19] Hernandez P, Johnson CA. Deferoxamine for aluminium toxicity in dialysis patients. *ANNA J* 1990;17(3):224–8.
- [20] Gross ML, Sweny P, Pearson RM, Kennedy J, Fernando ON, Moorhead JF. Rejection encephalopathy. An acute neurological syndrome complicating renal transplantation. *J Neurol Sci* 1982;56(1):23–34.
- [21] Gross ML, Pearson R, Sweny P, Fernando ON, Moorhead JF. Rejection encephalopathy. *Proc Eur Dial Transplant Assoc* 1981;18:461–4.
- [22] Port JD, Beauchamp Jr NJ. Reversible intracerebral pathologic entities mediated by vascular autoregulatory dysfunction. *Radiographics* 1998;18(2):353–67.
- [23] Eschbach JW, Abdulhadi MH, Browne JK, Delano BG, Downing MR, Egrie JC, et al. Recombinant human erythropoietin in anemic patients with end-stage renal disease. Results of a phase III multicenter clinical trial. *Ann Intern Med* 1989;111(12):992–1000.
- [24] Sikole A, Spasovski G, Zafirov D, Polenakovic M. Epoetin omega for treatment of anemia in maintenance hemodialysis patients. *Clin Nephrol* 2002;57(3):237–45.
- [25] Delanty N, Vaughan C, Frucht S, Stubgen P. Erythropoietin-associated hypertensive posterior leukoencephalopathy. *Neurology* 1997;49(3):686–9.
- [26] Raine AE, Roger SD. Effects of erythropoietin on blood pressure. *Am J Kidney Dis* 1991;18(4 Suppl 1):76–83.
- [27] Walter J, Gal J, Taraba I. The beneficial effect of low initial dose and gradual increase of erythropoietin treatment in hemodialysis patients. *Artif Organs* 1995;19(1):76–80.
- [28] Benna P, Lacquaniti F, Triolo G, Ferrero P, Bergamasco B. Acute neurologic complications of hemodialysis. Study of 14,000 hemodialyses in 103 patients with chronic renal failure. *Ital J Neurol Sci* 1981;2(1):53–7.
- [29] Silver SM, Sterns RH, Halperin ML. Brain swelling after dialysis: old urea or new osmoles? *Am J Kidney Dis* 1996;28(1):1–13.
- [30] Silver SM, DeSimone Jr JA, Smith DA, Sterns RH. Dialysis disequilibrium syndrome (DDS) in the rat: role of the "reverse urea effect". *Kidney Int* 1992;42(1):161–6.
- [31] Galons JP, Trouard T, Gmitro AF, Lien YH. Hemodialysis increases apparent diffusion coefficient of brain water in nephrectomized rats measured by isotropic diffusion-weighted magnetic resonance imaging. *J Clin Invest* 1996;98(3):750–5.
- [32] Pedrini LA, Zereik S, Rasmy S. Causes, kinetics and clinical implications of post-hemodialysis urea rebound. *Kidney Int* 1988;34(6):817–24.
- [33] Ichai C, Fenouil E, Grimaud D. Osmolality and brain. *Ann Fr Anesth Reanim* 1994;13(1):68–79.
- [34] Rivera-Vazques AB, Noriega-Sanchez A, Ramirez-Gonzalez R, Martinez-Maldonado M. Acute hypercalcemia in hemodialysis patients: distinction from 'dialysis dementia'. *Nephron* 1980;25(5):243–6.
- [35] Riggs JE. Neurologic manifestations of fluid and electrolyte disturbances. *Neurol Clin* 1989;7(3):509–23.
- [36] Ortiz A, Martin-Llonch N, Garron MP, Alberola ML, Caramelo C, Ortiz-Gonzalez A. Cefazolin-induced encephalopathy in uremic patients. *Rev Infect Dis* 1991;13(4):772–3.
- [37] Arik N, Cengiz N, Bilge A. Metronidazole-induced encephalopathy in a uremic patient: a case report. *Nephron* 2001;89(1):108–9.
- [38] Ifergane G, Masalha R, Zigulinski R, Merkin L, Wirguin I, Herishanu YO. Acute encephalopathy associated with vigabatrin monotherapy in patients with mild renal failure. *Neurology* 1998;51(1):314–5.
- [39] Muruve DA, Steinman TI. Contrast-induced encephalopathy and seizures in a patient with chronic renal insufficiency. *Clin Nephrol* 1996;45(6):406–9.
- [40] Peces R, de la Torre M, Alcazar R. Acyclovir-associated encephalopathy in haemodialysis. *Nephrol Dial Transplant* 1996;11(4):752.
- [41] Cheung WC, Lo CY, Lo WK, Ip M, Cheng IK. Isoniazid-induced encephalopathy in dialysis patients. *Tuber Lung Dis* 1993;74(2):136–9.
- [42] Tartini A, Kesselbrenner M. Encainide-induced encephalopathy in a patient with chronic renal failure. *Am J Kidney Dis* 1990;15(2):178–9.
- [43] Sica DA, Comstock TJ. Pseudoephedrine accumulation in renal failure. *Am J Med Sci* 1989;298(4):261–3.
- [44] Vanholder R, Van Landschoot N, De Smet R, Schoots A, Ringoir S. Drug protein binding in chronic renal failure: evaluation of nine drugs. *Kidney Int* 1989;33(5):996–1004.
- [45] Chang SH, Lim CS, Low TS, Chon HT, Tan SY. Cyclosporine-associated encephalopathy: a case report and literature review. *Transplant Proc* 2001;33(7-8):3700–1.
- [46] Parvex P, Pinsk M, Bell LE, O'Gorman AM, Patenoude YG, Gupta IR. Reversible encephalopathy associated with tacrolimus in pediatric renal transplants. *Pediatr Nephrol* 2001;16(7):537–42.
- [47] Paizel PM, Snoeck HW, van den Hauwe L, Boven K, Bosmans JL, Van Goethem JW, et al. Cerebral complications of murine monoclonal CD3 antibody (OKT3): CT and MR findings. *AJNR* 1997;18(10):1935–8.
- [48] Pirsch JD, Miller J, Deierhoi MH, Vincenti F, Filo RS. A comparison of tacrolimus (FK506) and cyclosporine for immunosuppression after cadaveric renal transplantation FK506 Kidney Transplant Study Group. *Transplantation* 1997;63(7):977–83.
- [49] Scheel AK, Blaschke S, Schettler V, Mayer C, Muller GA, Bittermann HJ, et al. Severe neurotoxicity of tacrolimus (FK506) after renal transplantation: two case reports. *Transplant Proc* 2001;33(78):3693–4.
- [50] Bechstein WO. Neurotoxicity of calcineurin inhibitors; impact and clinical management. *Transplant Int* 2000;13(5):313–26.
- [51] Inoha S, Inamura T, Nakamizo A, Ikezaki K, Amono T, Fukui M. Magnetic resonance imaging in cases with encephalopathy secondary to immunosuppressive agents. *J Clin Neurosci* 2002;9(3):305–7.
- [52] Furukawa M, Terae S, Chu BC, Kaneko K, Kamada H, Miyasaka K. MRI in seven cases of tacrolimus FK-506-encephalopathy: utility of FLAIR and diffusion-weighted imaging. *Neuroradiology* 2001;43(8):615–21.

- [53] Bartynski WS, Zeigler Z, Spearman MP, Lin L, Shaddock RK, Lister J. Etiology of cortical and white matter lesions in cyclosporin-A and FK-506. *AJNR* 2001;22(10):1901–14.
- [54] Ikesue H, Kataoka Y, Kawachi R, Dohgu S, Shuto H, Oishi R. Cyclosporine enhances alpha1-adrenoceptor-mediated nitric oxide production in C6 glioma cells. *Eur J Pharmacol* 2000;407(3):221–6.
- [55] Chow KM, Wang AY, Hui AC, Wong TY, Szeto CC, Li PK. Non-convulsive status epilepticus in peritoneal dialysis patients. *Am J Kidney Dis* 2001;38(2):400–5.
- [56] Fukunishi I, Kitaoka T, Shirai T, Kino K, Kanematsu E, Sato Y. Psychiatric disorders among patients undergoing hemodialysis therapy. *Nephron* 2002;91(2):344–7.
- [57] Lass P, Buscombe JR, Harber M, Davenport A, Hinson AJ. Cognitive impairment in patients with renal failure is associated with multiple-infarct dementia. *Clin Nucl Med* 1999;24(8):561–5.
- [58] Rob PM, Niederstadt C, Reusche E. Dementia in patients undergoing long-term dialysis: aetiology, differential diagnosis, epidemiology and management. *CNS Drugs* 2001;15(9):691–9.
- [59] Savazzi GM, Cusmano F, Vinci S, Allegri L. Progression of cerebral atrophy in patients on regular hemodialysis treatment: long-term follow-up with cerebral computed tomography. *Nephron* 1995;69(1):29–33.
- [60] Savazzi GM, Cusmano F, Degasperis T. Cerebral atrophy in patients on long-term regular hemodialysis treatment. *Clin Nephrol* 1985;23(2):89–95.
- [61] Kretzschmar K, Nix W, Zschiedrich H, Philipp T. Morphologic cerebral changes in patients undergoing dialysis for renal failure. *AJNR* 1983;4(3):439–41.
- [62] Savazzi GM, Cusmano F, Bergamaschi E, Vinci S, Allegri L, Garini G. Hypertension as an etiopathological factor in the development of cerebral atrophy in hemodialyzed patients. *Nephron* 1999;81(1):17–24.
- [63] Savazzi GM. Pathogenesis of cerebral atrophy in uraemia. *State of the art. Nephron* 1988;49(2):94–103.
- [64] Savazzi GM, Cusmano F, Musini S. Cerebral imaging changes in patients with chronic renal failure treated conservatively or in hemodialysis. *Nephron* 2001;89(1):31–6.
- [65] Capron L, Grateau G. Accelerated arterial disease in renal transplant recipients. *Nephrol Dial Transplant* 1998;13(Suppl 4):49–50.
- [66] Iseki K, Fukiyama K. Clinical demographics and long-term prognosis after stroke in patients on chronic hemodialysis. The Okinawa Dialysis Study Group. *Nephrol Dial Transplant* 2000;15(11):1808–13.
- [67] Chung AK, Sarnak MJ, Yan G, Dwyer JT, Heyka RJ, Rocco MV, et al. Atherosclerotic cardiovascular disease risks in chronic hemodialysis patients. *Kidney Int* 2000;58(1):353–62.
- [68] De Deyn PP, Vanholder R, D'Hooge R. Nitric oxide in uremia: effects of several potentially toxic guanidino compounds. *Kidney Int Suppl* 2003;84:25–8.
- [69] Jungers P, Massy ZA, Khoa TN, Fumeron C, Labrunie M, Lacour B, et al. Incidence and risk factors of atherosclerotic cardiovascular accidents in predialysis chronic renal failure patients: a prospective study. *Nephrol Dial Transplant* 1997;12(12):2597–602.
- [70] Jungers P, Chauveau P, Bandin O, Chadefaux B, Aupetit J, Labrunie M, et al. Hyperhomocysteinemia is associated with atherosclerotic occlusive arterial accidents in predialysis chronic renal failure patients. *Miner Electrolyte Metab* 1997;23(3-6):170–3.
- [71] Perna AF, Ingrosso D, Castaldo P, De Santo NG, Galletti P, Zappia V. Homocysteine, a new crucial element in the pathogenesis of uremic cardiovascular complications. *Miner Electrolyte Metab* 1999;25(1/2):95–9.
- [72] Druke TB, Massy ZA. Advanced oxidation protein products, parathyroid hormone and vascular calcification in uremia. *Blood Purif* 2002;20(5):494–7.
- [73] Segarra G, Medina P, Ballester RM, Lluch P, Aldasoro M, Vila JM, et al. Effects of some guanidino compounds on human cerebral arteries. *Stroke* 1999;30(10):2206–10.
- [74] Torremans A, Van de Vijver G, Vanholder R, Marescau B, D'Hooge R, De Deyn PP, et al. Effect of NaCN on currents evoked by uremic retention solutes in dissociated mouse neurons. *Brain Res* 2004;1008(1):107–12.
- [75] Massy ZA, Borderie D, Nguyen-Khoa T, Druke TB, Ekindjian OG, Lacour B. Increased plasma S-nitrosothiol levels in chronic haemodialysis patients. *Nephrol Dial Transplant* 2003;18(8):153–7.
- [76] Massy ZA, Fumeron C, Borderie D, Tuppin P, Nguyen-Khoa T, Benoit MO, et al. Increased plasma S-nitrosothiol concentrations predict cardiovascular outcomes among patients with end-stage renal disease: a prospective study. *J Am Soc Nephrol* 2004;15(2):470–6.
- [77] Peppas M, Uribarri J, Cai W, Lu M, Vlassara H. Glycoxidation and inflammation in renal failure patients. *Am J Kidney Dis* 2004;43(4):690–5.
- [78] Vicca S, Massy ZA, Hennequin C, Rihane D, Nguyen-Khoa T, Druke TB, et al. New insights into the effects of the protein moiety of oxidized LDL. *Kidney Int Suppl* 2003;84:S125–7.
- [79] Nguyen-Khoa T, Massy ZA, De Bandt JP, Kebede M, Salama L, Lambrey G, et al. Oxidative stress and haemodialysis: role of inflammation and duration of dialysis treatment. *Nephrol Dial Transplant* 2001;16(2):335–40.
- [80] Uribarri J, Peppas M, Cai W, Goldberg T, Lu M, Baliga S, et al. Dietary glycotoxins correlate with circulating advanced glycation end product levels in renal failure patients. *Am J Kidney Dis* 2003;42(3):532–8.
- [81] van Ypersele de Strihou C. Advanced glycation in uraemic toxicity. *EDTNA ERCA J* 2003;29(3):148–50.
- [82] Lin CL, Huang CC, Yu CC, Yang HY, Chuang FR, Yang CW. Reduction of advanced glycation end product levels by on-line hemodiafiltration in long-term hemodialysis patients. *Am J Kidney Dis* 2003;42(3):524–31.
- [83] Graham IM, Daly LE, Refsum HM, Robinson K, Brattstrom LE, Ueland PM, et al. Plasma homocysteine as a risk factor for vascular disease. The European Concerted Action Project. *JAMA* 1997;267(22):1775–81.
- [84] Perna AF, Castaldo P, Ingrosso D, De Santo NG. Homocysteine, a new cardiovascular risk factor, is also a powerful uremic toxin. *J Nephrol* 1999;12(4):230–40.
- [85] Fellah H, Feki M, Hsairi M, Sanhaji H, Kaabachi N, Ben Abdallah T, et al. Hyperhomocysteinemia and end-stage renal disease: determinants and association with cardiovascular disease in Tunisian patients. *Clin Chem Lab Med* 2003;41(5):675–80.
- [86] Perna AF, Ingrosso D, De Santo NG, Galletti P, Brunone M, Zappia V. Metabolic consequences of folate-induced reduction of hyperhomocysteinemia in uremia. *J Am Soc Nephrol* 1997;8(12):1899–905.
- [87] Jungers P, Joly D, Massy Z, Chauveau P, Nguyen AT, Aupetit J, Chadefaux B. Sustained reduction of hyperhomocysteinemia with folic acid supplementation in predialysis patients.
- [88] Van Guldener C, Janssen MJ, Lambert J, ter Wee PM, Donker AJ, Stehouwer CD. Folic acid treatment of hyperhomocysteinemia in peritoneal dialysis patients: no change in endothelial function after long-term therapy. *Perit Dial Int* 1998;18(3):282–9.
- [89] Van Guldener C, Janssen MJ, Lambert J, ter Wee PM, Jakobs C, Donker AJ, et al. No change in impaired endothelial function after long-term folic acid therapy of hyperhomocysteinemia in haemodialysis patients. *Nephrol Dial Transplant* 1998;13(1):106–12.
- [90] Bostom AG, Shemin D, Bagley P, Massy ZA, Zannabli A, Christopher K, et al. Controlled comparison of L-5-methyltetrahydrofolate versus folic acid for the treatment of hyperhomocysteinemia in hemodialysis patients. *Circulation* 2000;101(24):2829–32.
- [91] Massy ZA. Potential strategies to normalize the levels of homocysteine in chronic renal failure patients. *Kidney Int Suppl* 2003;84:S134–6.
- [92] Van Telligen A, Grooteman MP, Bartels PC, Van Limbeek J, Van Guldener C, Wee PM, et al. Long-term reduction of plasma ho-

- homocysteine levels by super-flux dialyzers in hemodialysis patients. *Kidney Int* 2001;59(1):342–7.
- [93] Galli F, Benedetti S, Buoncristiani U, Piroddi M, Conte C, Canestrari F, et al. The effect of PMMA-based protein-leaking dialyzers on plasma homocysteine levels. *Kidney Int* 2003;64(2):748–55.
- [94] De Vriese AS, Langlois M, Bernard D, Geerolf I, Stevens L, Boelaert JR, et al. Effect of dialyser membrane pore size on plasma homocysteine levels in haemodialysis patients. *Nephrol Dial Transplant* 2003;18(12):2596–600.
- [95] Locatelli F, Cannata-Andia JB, Drueke TB, Horl WH, Fouque D, Heimbürger O, et al. Management of disturbances of calcium and phosphate metabolism in chronic renal insufficiency, with emphasis on the control of hyperphosphataemia. *Nephrol Dial Transplant* 2002;17(5):723–31.
- [96] Massy ZA, Keane WF. Pathogenesis of atherosclerosis. *Semin Nephrol* 1996;16(1):12–20.
- [97] Parfrey PS. Cardiac and cerebrovascular disease in chronic uremia. *Am J Kidney Dis* 1993;21(1):77–80.
- [98] Jungers P, Qualim Z, Nguyen-Koa T, Massy Z, London G. Cardioprotection: an essential component for predialysis chronic renal failure treatment. *Nephrologie* 2003;24(2):79–88.
- [99] Agraharkar M, Martinez MA, Kuo YF, Ahuja TS. Hospitalisation for initiation of maintenance hemodialysis. *Nephron Clin Pract* 2004;97(2):c54–60.
- [100] Chang MH, Chou KJ. The role of autonomic neuropathy in the genesis of intradialytic hypotension. *Am J Nephrol* 2001;21(5):357–61.
- [101] Warlow CP, Dennis MS, van Gijn J, Hankey GJ, Sandercock PAG, Bamford JM, et al. A practical guide to management. Oxford: Blackwell Science Ltd.; 2002 (pp. 255–258).
- [102] Knoll GA, Grabowski JA, Dervin GF, O'Rourke K. A randomized, controlled trial of albumin versus saline for the treatment of intradialytic hypotension. *J Am Soc Nephrol* 2004;15(2):487–92.
- [103] Hoeben H, Abu-Alfa AK, Mahnensmith R, Perazella MA. Hemodynamics in patients with intradialytic hypotension treated with cool dialysate or midodrine. *Am J Kidney Dis* 2002;39(1):102–7.
- [104] Brewster UC, Ciampi MA, Abu-Alfa AK, Perazella MA. Addition of sertraline to other therapies to reduce dialysis-associated hypotension. *Nephrology* 2003;8(6):296–301.
- [105] Abramson JL, Jurkovic CT, Vaccarino V, Weintraub WS, McClellan W. Chronic kidney disease, anemia, and incident stroke in a middle-aged, community-based population: the ARIC study. *Kidney Int* 2003;64(2):610–5.
- [106] Drueke TB. Aspects of cardiovascular burden in pre-dialysis patients. *Nephron* 2000;85(Suppl 1):9–14.
- [107] Di Minno G, Martinez J, McKean ML, De La Rosa J, Burke JF, Murphy S. Platelet dysfunction in uremia. Multifaceted defect partially corrected by dialysis. *Am J Med* 1985;79(5):552–9.
- [108] Kawamura M, Fijimoto S, Hisanaga S, Yamamoto Y, Eto T. Incidence, outcome, and risk factors of cerebrovascular events in patients undergoing maintenance hemodialysis. *Am J Kidney Dis* 1998;31(6):991–6.
- [109] Iseki K, Kinjo K, Kimura Y, Osawa A, Fukiyama K. Evidence for high risk of cerebral hemorrhage in chronic dialysis patients. *Kidney Int* 1993;44(5):1086–90.
- [110] Wijdicks EF, Torres VE, Schievink WI, Sterioff S. Cerebral hemorrhage in recipients of renal transplantation. *Mayo Clin Proc* 1999;74(11):1111–2.
- [111] Janssen MJ, van der Meulen J. The bleeding risk in chronic haemodialysis: preventive strategies in high-risk patients. *Neth J Med* 1996;48(5):198–207.
- [112] Onoyama K, Ibayashi S, Nanishi F, Okuda S, Oh Y, Hirakata H, et al. Cerebral hemorrhage in patients on maintenance hemodialysis. CT analysis of 25 cases. *Eur Neurol* 1987;26(3):171–5.
- [113] Iseki K, Fukiyama K. Predictors of stroke in patients receiving chronic hemodialysis. *Kidney Int* 1996;50(5):1672–5.
- [114] Da Silva AF, Escofet X, Rutherford PA. Medical adjuvant treatment to increase patency of arteriovenous fistulae and grafts. *Cochrane Database Syst Rev* 2003;(2):CD002786.
- [115] Lieske JC, Toback FG. Autosomal dominant polycystic kidney disease. *J Am Soc Nephrol* 1993;3(8):1442–50.
- [116] Graf S, Schischma A, Eberhardt KE, Istel R, Stiasny B, Schulze BD. Intracranial aneurysms and dolichoectasia in autosomal dominant polycystic kidney disease. *Nephrol Dial Transplant* 2002;17(5):819–23.
- [117] Belz MM, Hughes RL, Kaehny WD, Johnson AM, Fick-Brosnahan GM, Earnest MP, et al. Familial clustering of ruptured intracranial aneurysms in autosomal dominant polycystic kidney disease. *Am J Kidney Dis* 2001;38(4):770–6.
- [118] Schievink WI, Torres VE, Wiebers DO, Huston 3rd J. Intracranial arterial dolichoectasia in autosomal dominant polycystic kidney disease. *J Am Soc Nephrol* 1997;8(8):1298–303.
- [119] Yorioka N, Oda H, Ogawa T, Taniguchi Y, Kushihata S, Takemasa A, et al. Continuous ambulatory peritoneal dialysis is superior to hemodialysis in chronic dialysis patients with cerebral hemorrhage. *Nephron* 1994;67(3):365–6.
- [120] Leonard A, Shapiro FL. Subdural hematoma in regularly hemodialyzed patients. *Ann Intern Med* 1975;82(5):650–8.
- [121] Inzelberg R, Neufeld MY, Reider I, Gari P. Non surgical treatment of subdural hematoma in a hemodialysis patient. *Clin Neurol Neurosurg* 1989;91(1):85–9.
- [122] Tietjen DP, Moore Jr J, Gouge SF. Hemodialysis-associated acute subdural hematoma. Iterim management with peritoneal dialysis. *Am J Nephrol* 1987;7(6):478–81.
- [123] Bidwell G, Sherrard D, Mathews M. Peritoneal dialysis: a temporizing means for hemodialysis patients with subdural hematomas. *Nephron* 1977;18(6):352–3.
- [124] Kilinc M, Benli US, Can U. Osmotic myelinolysis in a normonatremic patient. *Acta Neurol Belg* 2002;102(2):87–9.
- [125] Pradhan S, Jha R, Singh MN, Gupta S, Phadke RV, Kher V. Central pontine myelinolysis following 'slow' correction of hyponatremia. *Clin Neurol Neurosurg* 1995;97(4):340–3.
- [126] Loo CS, Lim TO, Fan KS, Murad Z, Suleiman AB. Pontine myelinolysis following correction of hyponatremia. *Med J Malaysia* 1995;50(2):180–2.
- [127] Artieda J, Muruzabal J, Larumbe R, Garcia de Casasola C, Obeso JA. Cortical mechanisms mediating asterixis. *Mov Disord* 1992;7(3):209–16.
- [128] Massey EW, Bowman MH, Rozear MP. Asterixis mimicking drop attacks in chronic renal failure. *Neurology* 1988;38(4):663.
- [129] Andermann E, Andermann F, Carpenter S, Wolfe LS, Nelson R, Patry G, et al. Action myoclonus-renal failure syndrome: a previously unrecognized neurological disorder unmasked by advances in nephrology. *Adv Neurol* 1986;43:87–103.
- [130] Chadwick D, French AT. Uraemic myoclonus: an example of reticular reflex myoclonus? *J Neurol Neurosurg Psychiatry* 1979;42(1):52–5.
- [131] Hung SC, Hung SH, Tarng DC, Yang WC, Huang TP. Chorea induced by thiamine deficiency in hemodialysis patients. *Am J Kidney Dis* 2001;37(2):426–30.
- [132] Wang HC, Brown P, Lees AJ. Acute movement disorders with bilateral basal ganglia lesions in uremia. *Mov Disord* 1998;13(6):952–7.
- [133] Collado-Seidel V, Kohlen R, Samtleben W, Hillebrand GF, Oertel WH, Trenkwalder C. Clinical and biochemical findings in uremic patients with and without restless legs syndrome. *Am J Kidney Dis* 1998;31(2):324–8.
- [134] Winkelmann JW, Chertow GM, Lazarus JM. Restless legs syndrome in end-stage renal disease. *Am J Kidney Dis* 1996;28(3):372–8.
- [135] Kerr PG, van Bakel C, Dawborn JK. Assessment of the symptomatic benefit of cool dialysate. *Nephron* 1989;52:166–9.
- [136] Wetter TC. Restless legs syndrome: a review for the renal care professionals. *EDTNA ERCA J* 2001;26(1):42–6.

- [137] Joy MS. Clonazepam: benzodiazepine therapy for the restless legs syndrome. *ANNA J* 1997;24(6):686–9.
- [138] Ausserwinkler M, Schmidt P. Successful clonidine treatment of restless leg syndrome in chronic kidney insufficiency. *Schweiz Med Wochenschr* 1989;119(6):184–6.
- [139] Janzen L, Rich JA, Vercaigne LM. An overview of levodopa in the management of restless legs syndrome in a dialysis population: pharmacokinetics, clinical trials, and complications of therapy. *Ann Pharmacother* 1999;33(1):86–92.
- [140] Winkelmann FJ, Stautner A, Samtleben W, Trenkwalder C. Long-term course of restless legs syndrome in dialysis patients after kidney transplantation. *Mov Disord* 2002;17(5):1072–6.
- [141] Barczyk MP, Lebkowski WJ, Mariak Z, Malyszko J, Mysliwiec M. Brain abscess as a rare complication in a hemodialysed patient. *Med Sci Monit* 2001;7(6):1329–33.
- [142] Gupta SK, Manjunath-Prasad KS, Sharma BS, Khosla VK, Kak VK, Minz M, et al. Brain abscess in renal transplant recipients: report of three cases. *Surg Neurol* 1997;48(3):284–7.
- [143] Wong KM, Chak WL, Chan YH, Choi KS, Chau KF, Lee KC, et al. Subcutaneous nodules attributed to nocardiosis in a renal transplant recipient on tacrolimus therapy. *Am J Nephrol* 2000;20(2):138–41.
- [144] Mrowka C, Heintz B, Weis J, Mayfrank L, Reul J, Sieberth HG. Isolated cerebral aspergilloma: long-term survival of a renal transplant recipient. *Clin Nephrol* 1997;47(6):394–6.
- [145] Bruno A, Adams Jr HP. Neurologic problems in renal transplant recipients. *Neurol Clin* 1988;6(2):305–25.
- [146] Irie T, Kasai M, Abe N, Seto K, Naojara T, Kawamura K, et al. Cerebellar form of progressive multifocal leukoencephalopathy in a patient with chronic renal failure. *Intern Med* 1992;31(2):218–23.
- [147] Reis MA, Costa RS, Ferraz AS. Causes of death in renal transplant recipients: a study of 102 autopsies from 1968 to 1991. *J R Soc Med* 1995;88(1):24–7.
- [148] Vanholder R, Ringoir S. Infectious morbidity and defects of phagocytic function in end-stage renal disease: a review. *J Am Soc Nephrol* 1993;3(9):1541–54.
- [149] Kolmos HJ. Spinal epidural abscess in patients on maintenance haemodialysis (a presentation of two cases). *Int Urol Nephrol* 1979;11(3):249–53.
- [150] Cengiz K. Increased incidence of neoplasia in chronic renal failure (20-year experience). *Int Urol Nephrol* 2002;33(1):121–6.
- [151] Bosmans JL, Ysebaert D, De Cock AM, Hauben E, Muylle L, Schrijvers D, et al. Interferon-alpha and the cure of metastasis of a malignant meningioma in a kidney allograft recipient: a case report. *Transplant Proc* 1997;29(1/2):838.
- [152] Urasaki E, Yamada H, Tokimura T, Yokota A. T-cell type primary spinal intramedullary lymphoma associated with human T-cell lymphotropic virus type I after renal transplant: case report. *Neurosurgery* 1996;38(5):1036–9.
- [153] Schwachheimer K, Hashemian A. Neuropathologic findings after organ transplantation. An autopsy study. *Gen Diagn Pathol* 1995;141(1):35–9.
- [154] Hacker SM, Knight BP, Lunde NM, Gratiot-Deans J, Sandler H, Leichtman AB. A primary central nervous system T-cell lymphoma in a renal transplant patient. *Transplantation* 1992;53(3):691–2.
- [155] Kwan JT, Cotter FE, Pollock LE, Altmann P, Lord RH, Raftery MJ, et al. EBV-genome positive monoclonal B cell cerebral lymphoma in a renal allograft recipient following OKT3 therapy. *Nephrol Dial Transplant* 1992;7(4):360–1.
- [156] Nalesnik MA. The diverse pathology of post-transplant lymphoproliferative disorders: the importance of a standardized approach. *Transplant Infect Dis* 2001;3(2):88–96.
- [157] Gill D, Juffs HG, Herzig KA, Brown AM, Hawley CM, Cobcroft RG, et al. Durable and high rates of remission following chemotherapy in posttransplantation lymphoproliferative disorders after renal transplantation. *Transplant Proc* 2003;35(1):256–7.
- [158] Porcu P, Eisenbeis CF, Pelletier RP, Davies EA, Baiocchi RA, Roychowdhury S, et al. Successful treatment of posttransplantation lymphoproliferative disorder (PTLD) following renal allografting is associated with sustained CD8(+) T-cell restoration. *Blood* 2002;100(7):2341–8.
- [159] Miller Jr WT, Siegel SG, Montone KT. Posttransplantation lymphoproliferative disorder: changing manifestations of disease in a renal transplant population. *Crit Rev Diagn Imaging* 1997;38(6):569–85.
- [160] Keogh PV, Fisher V, Flint SR. Resolution of oral non-Hodgkin's lymphoma by reduction of immunosuppressive therapy in a renal allograft recipient: a case report and review of the literature. *Oral Surg Oral Med Oral Pathol Oral Radiol Endod* 2002;94(6):697–701.
- [161] Penn I, Porat G. Central nervous system lymphomas in organ allograft recipients. *Transplantation* 1995;59(2):240–4.
- [162] Maisonneuve P, Agodoa L, Gellert R, Stewart JH, Buccianti G, Lowenfels AB, et al. Cancer in patients on dialysis for end-stage renal disease: an international collaborative study. *Lancet* 1999;354(9173):93–9.
- [163] Evan RW, Mokri B. Spontaneous intracranial hypotension resulting in coma. *Headache* 2002;42(2):159–60.
- [164] Mokri B. Spontaneous intracranial hypotension. *Curr Neurol Neurosci Rep* 2001;1(2):109–17.
- [165] Thomke F, Bredel-Geissler A, Mika-Gruttner A, Muller-Forell W, Andreas J, Kuhl V, et al. Spontaneous intracranial hypotension syndrome. Clinical, neuroradiological and cerebrospinal fluid findings. *Nervenarzt* 1999;70(10):909–15.
- [166] Binder DK, Dillon WP, Fishman RA, Schmidt MH. Intrathecal saline infusion in the treatment of obtundation associated with spontaneous intracranial hypotension: technical case report. *Neurosurgery* 2002;51(3):836–7.
- [167] Spelle L, Boulin A, Tainturier C, Visot A, Graveleau P, Pierot L. Neuroimaging features of spontaneous intracranial hypotension. *Neuroradiology* 2001;43(8):622–7.
- [168] Ferrante E, Riva M, Gatti A, Brioschi A, Guccione A, Colombo N, et al. Intracranial hypotension syndrome: neuroimaging in five spontaneous cases and etiopathogenetic correlations. *Clin Neurol Neurosurg* 1998;100(1):33–9.
- [169] Guy J, Johnston PK, Corbett JJ, Day AL, Glaser JS. Treatment of visual loss in pseudotumor cerebri associated with uremia. *Neurology* 1990;40(1):28–32.
- [170] Chang D, Nagamoto G, Smith WE. Benign intracranial hypertension and chronic renal failure. *Cleve Clin J Med* 1992;59(4):419–22.
- [171] Korzets A, Gafer U, Floru S, Chagnac A, Zevin D. Deteriorating renal function with acetazolamide in a renal transplant patient with pseudotumor cerebri. *Am J Kidney Dis* 1993;21(3):322–4.
- [172] Garcia S, Cofan F, Combalia A, Campistol JM, Oppenheimer F, Ramon R. Compression of the ulnar nerve in Guyon's canal by uremic tumoral calcinosis. *Arch Orthop Trauma Surg* 2000;120(3/4):228–30.
- [173] Mourad G, Argiles A. Renal transplantation relieves the symptoms but does not reverse beta 2-microglobulin amyloidosis. *J Am Soc Nephrol* 1996;7(5):798–804.
- [174] Floege J, Ketteler M. Beta2-microglobulin-derived amyloidosis: an update. *Kidney Int Suppl* 2001;78:S164–71.
- [175] Hirasawa Y, Ogura T. Carpal tunnel syndrome in patients on long-term haemodialysis. *Scand J Plast Surg Hand Surg* 2000;34(4):373–81.
- [176] Druke TB. Beta2-microglobulin and amyloidosis. *Nephrol Dial Transplant* 2000;15(Suppl 1):17–24.
- [177] Chary-Valckenaere I, Kessler M, Mainard D, Schertz L, Chanliou J, Champigneulle J, et al. Amyloid and non-amyloid carpal tunnel syndrome in patients receiving chronic renal dialysis. *J Rheumatol* 1998;25(6):1164–70.
- [178] Gejyo F, Kimura H, Suzuki S, Miyazaki R, Naiki H, Nakakuki K. Apolipoprotein E and alpha 1-antichymotrypsin in dialysis-related amyloidosis. *Kidney Int Suppl* 1997;62:S75–8.

- [179] Cofan F, Garcia S, Combalia S, Combalia A, Segur JM, Oppenheimer F. Carpal tunnel syndrome secondary to uraemic tumoral calcinosis. *Rheumatology (Oxford)* 2002;41(6):701–3.
- [180] Kumar S, Trivedi HL, Smith EK. Carpal tunnel syndrome: a complication of arteriovenous fistula in hemodialysis patients. *Can Med Assoc J* 1975;113(11–12):1070–2.
- [181] Vaziri ND, Barton CH, Ravikumar GR, Martin DC, Ness R, Saiki J. Femoral neuropathy: a complication of renal transplantation. *Nephron* 1981;28(1):30–1.
- [182] Vaziri ND, Barnes J, Khosrow M, Ehrlich R, Rosen SM. Compression neuropathy subsequent to renal transplantation. *Urology* 1976;7(2):145–7.
- [183] Sharma KR, Cross J, Santiago F, Ayyar DR, Burke G. Incidence of acute femoral neuropathy following renal transplantation. *Arch Neurol* 2002;59(4):541–5.
- [184] Galassi G, Ferrari S, Cobelli M, Rizzuto N. Neuromuscular complications of kidney diseases. *Nephrol Dial Transplant* 1998;13(Suppl 7):41–7.
- [185] Dumitru D, Amato A, Zwarts M. *Electrodiagnostic Medicine*. Philadelphia: Hanley & Belfus; 2002 (pp. 984–986).
- [186] Lindblom U, Tegner R. Thermal sensitivity in uremic neuropathy. *Acta Neurol Scand* 1985;71(4):290–4.
- [187] Tegner R, Lindholm B. Vibratory perception threshold compared with nerve conduction velocity in the evaluation of uremic neuropathy. *Acta Neurol Scand* 1985;71(4):284–9.
- [188] Yosipovitch G, Yarnitsky D, Mermelstein V, Sprecher E, Reiss J, Witenberg C, et al. Paradoxical heat sensation in uremic polyneuropathy. *Muscle Nerve* 1995;18(7):768–71.
- [189] Chang MH, Chou KJ. The role of autonomic neuropathy in the genesis of intradialytic hypotension. *Am J Nephrol* 2001;21(5):357–61.
- [190] Solders G, Persson A, Wilczek H. Autonomic system dysfunction and polyneuropathy in nondiabetic uremia. A one-year follow-up study after renal transplantation. *Transplantation* 1986;41(5):616–9.
- [191] Vita G, Dattola R, Calabro R, Manna L, Venuto C, Toscano A, et al. Comparative analysis of autonomic and somatic dysfunction in chronic uraemia. *Eur Neurol* 1988;28(6):335–40.
- [192] Solders G, Persson A, Gutierrez A. Autonomic dysfunction in nondiabetic terminal uraemia. *Acta Neurol Scand* 1985;71(4):321–7.
- [193] Burgess ES. Cardiac vagal denervation in hemodialysis patients. *Nephron* 1982;30(3):228–30.
- [194] Warren DJ, Naik RB, Mathias CJ. Vagal function in patients with chronic renal failure. *Contrib Nephrol* 1984;41:199–222.
- [195] Siamopoulos KC, Tsianos EV, Dardamanis M, Berecos C. Esophageal dysfunction in chronic hemodialysis patients. *Nephron* 1990;55(4):389–93.
- [196] Winkelmayer WC, Eigner M, Berger O, Grisold W, Leithner C. Optic neuropathy in uremia: an interdisciplinary emergency. *Am J Kidney Dis* 2001;37(3):23.
- [197] Mitz M, Prakash AS, Melvin J, Piering W. Motor nerve conduction indicators in uremic neuropathy. *Arch Phys Med Rehabil* 1980;61(1):45–8.
- [198] Charachon R, Moreno-Ribes V, Cordonnier D. Deafness due to renal failure. Clinicopathological study. *Ann Otolaryngol Chir Cervicofac* 1978;95(3):179–203.
- [199] Mitz M, Di Benedetto M, Klingbeil GE, Melvin JL, Piering W. Neuropathy in end-stage renal disease secondary to primary renal disease and diabetes. *Arch Phys Med Rehabil* 1984;65(5):235–8.
- [200] Laaksonen S, Metsarinne K, Voipio-Pulkki LM, Falck B. Neurophysiologic parameters and symptoms in chronic renal failure. *Muscle Nerve* 2002;25(6):884–90.
- [201] D'Amour ML, Dufresne LR, Morin C, Slaughter D. Sensory nerve conduction in chronic uremic patients during the first six months of hemodialysis. *Can J Neurol Sci* 1984;11(2):269–71.
- [202] Laaksonen S, Voipio-Pulkki L, Erkinjuntti M, Asola M, Falck B. Does dialysis therapy improve autonomic and peripheral nervous system abnormalities in chronic uraemia? *J Intern Med* 2000;248(1):21–6.
- [203] Ogura T, Makinodan A, Kubo T, Hayashida T, Hirasawa Y. Electrophysiological course of uraemic neuropathy in haemodialysis patients. *Postgrad Med J* 2001;77(909):451–4.
- [204] Robles NR, Murga L, Galvan S, Esparrago JF, Sanchez-Casado E. Hemodialysis with cuprophane or polysulfone: effects on uremic polyneuropathy. *Am J Kidney Dis* 1993;21(3):282–7.
- [205] Bolton CF. Electrophysiologic changes in uremic neuropathy after successful renal transplantation. *Neurology* 1976;26(2):152–61.
- [206] Hupperts RM, Leunissen KM, van Hooff JP, Lodder J. Recovery of uremic neuropathy after renal transplantation. *Clin Neurol Neurosurg* 1990;92(1):87–9.
- [207] Read DJ, Feest TG, Holman RH. Vibration sensory threshold: a guide to adequacy of dialysis? *Proc Eur Dial Transplant Assoc* 1983;19:253–7.
- [208] Okada H, Moriwaki K, Kanno Y, Sugahara S, Nakamoto H, Yoshizawa M, et al. Vitamin B6 supplementation can improve peripheral polyneuropathy in patients with chronic renal failure on high-flux haemodialysis and human recombinant erythropoietin. *Nephrol Dial Transplant* 2000;15(9):1410–3.
- [209] Kuwabara S, Nakazawa R, Azuma N, Suzuki M, Miyajima K, Fukutake T, et al. Intravenous methylcobalamin treatment for uremic and diabetic neuropathy in chronic hemodialysis patients. *Intern Med* 1999;38(6):472–5.
- [210] Hassan K, Simri W, Rubenchik I, Manelis J, Gross B, Shasha SM, et al. Effect of erythropoietin therapy on polyneuropathy in predialytic patients. *J Nephrol* 2003;16(1):121–5.
- [211] Mansouri B, Adybeig B, Rayegani M, Yasami S, Behshad V. Uremic neuropathy and the analysis of electrophysiological changes. *Electromyogr Clin Neurophysiol* 2001;41(2):107–15.
- [212] Amato AA, Barohn RJ, Sahenk Z, Tuschka PJ, Mendell JR. Polyneuropathy complicating bone marrow and solid organ transplantation. *Neurology* 1993;43(8):1513–8.
- [213] Campistol JM. Uremic myopathy. *Kidney Int* 2002;62(5):1901–13.
- [214] Moore GE, Parsons DB, Stray-Gundersen J, Painter PL, Brinker KR, Mitchell JH. Uremic myopathy limits aerobic capacity in hemodialysis patients. *Am J Kidney Dis* 1993;22(2):267–87.
- [215] Diesel W, Emms M, Knight BK, Noakes TD, Swaenepoel CR, van Zyl Smit R, et al. Morphologic features of the myopathy associated with chronic renal failure. *Am J Kidney Dis* 1993;22(5):677–84.
- [216] Lazaro RP, Kirshner HS. Proximal muscle weakness in uremia. Case reports and review of the literature. *Arch Neurol* 1980;37(9):555–8.
- [217] De Bisschop E, Allein S, Van der Niepen P, Verbeel en D, Luytpaert R, Osteaux M, et al. Effect of amino acid administration on uremic muscle metabolism: a <sup>31</sup>P-spectroscopy study. *Kidney Int* 1997;51(4):1182–7.
- [218] Montagnac R, Shillinger F, Billaud B, Monvoisin G. Myopathy in uremic patients. *Rev Rhum Mal Osteoartic* 1990;57(3):201–5.
- [219] Feinfeld DA, Kurian P, Cheng JT, Dilimetin G, Arriola MR, Ward L, et al. Effect of oral L-carnitine on serum myoglobin in hemodialysis patients. *Ren Fail* 1996;18(1):91–6.
- [220] Kunis CL, Markowitz GS, Liu-Jarin X, Fisher PE, Frei GL, D'Agati VD. Painful myopathy and end-stage renal disease. *Am J Kidney Dis* 2001;37(5):1098–104.
- [221] Fahal IH, Bell GM, Bone JM, Edwards RH. Physiological abnormalities of skeletal muscle in dialysis patients. *Nephrol Dial Transplant* 1997;12(1):119–26.