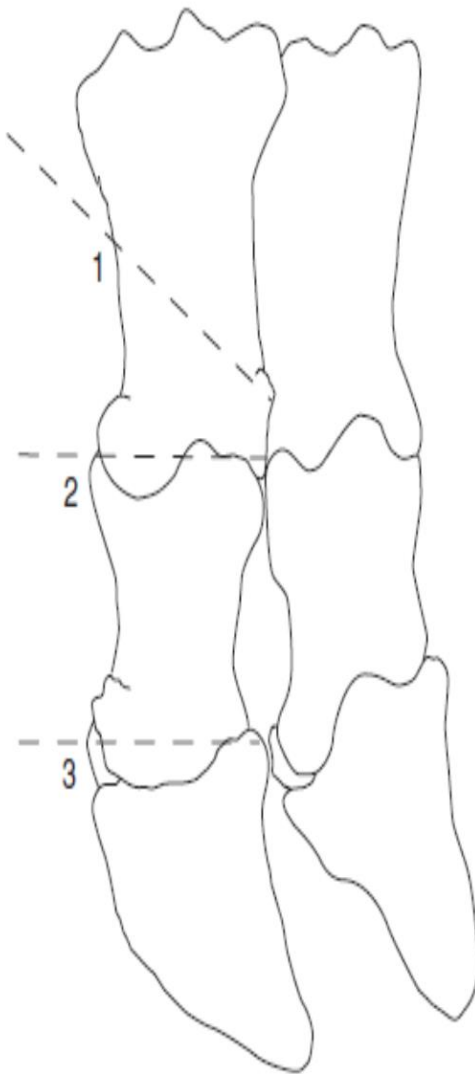


# Bovine Digital Amputation Methods

## ❖ Amputation through distal third of proximal phalanx

Method of amputation obliquely through distal third of proximal phalanx without preservation of skin flap is preferred method:

- Apply tourniquet above fetlock or hock, if not already in position for IVRA
- Incise interdigital space close to affected digit along whole length, continuing proximally 3 cm dorsally, and 2.5 cm at plantar aspect
- Insert embryotomy (obstetrical) wire into incision and adjust to a level 1–2 cm above axial aspect of proximal interphalangeal joint
- With assistant firmly holding digit down towards ground, saw rapidly at an oblique angle so that cut emerges 2–3 cm above abaxial joint level, continuing through skin
- Trim off protruding interdigital fat pad
- Twist off any major vessels e.g. dorsal digital artery lying axially
- Examine cut surface meticulously for signs of S.C. abscessation and necrosis, peritendinous infection and septic tenosynovitis
- Massage distally along deep flexor tendon sheath to check synovia
- Purulent synovia should be irrigated out of tendon sheath (male dog catheter, 50 ml syringe and saline), and reconsider need for resection of part of deep flexor tendon
- Dress wound with oxytetracycline or sulphadimidine powder (not essential), apply gauze swab or paraffin-impregnated tulle, and hold in place by pressure bandage and possibly protect by waterproof covering (e.g. duct tape)
- In bandaging avoid pressure necrosis around accessory digits
- Remove tourniquet
- Inject single prophylactic dose of ceftiofur or long-acting oxytetracycline and, in known risk areas, tetanus antitoxin



**Figure 7.7** Sites for digital amputation or disarticulation.

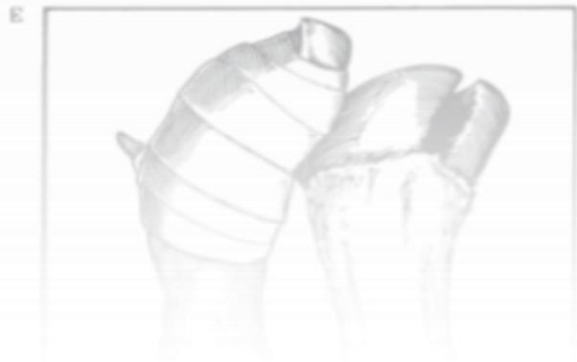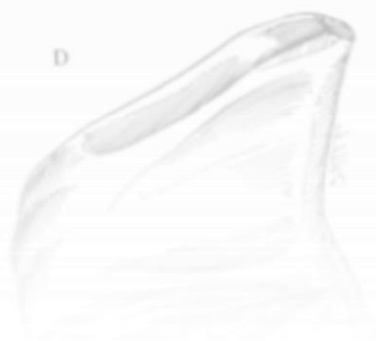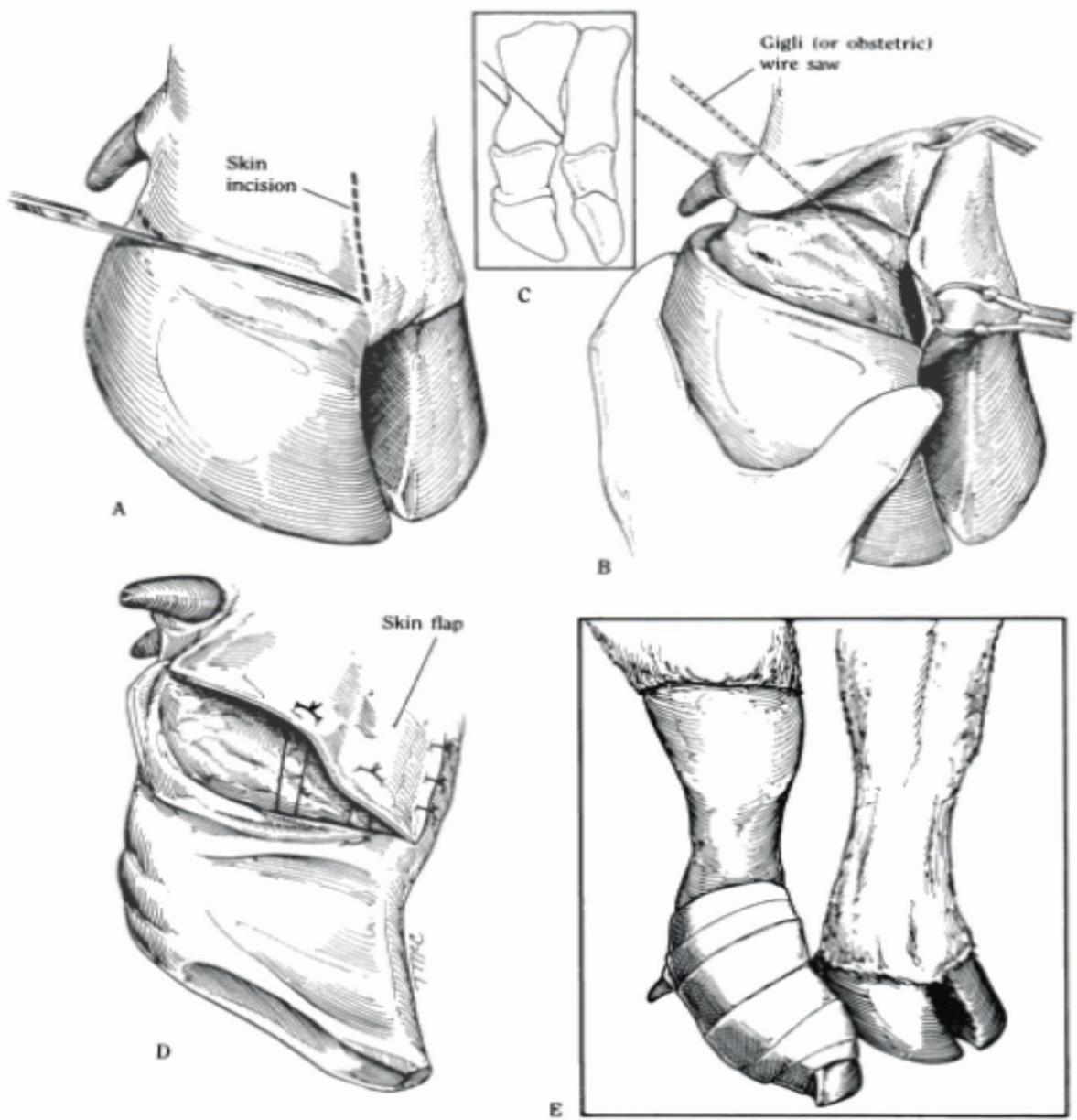
1. amputation with oblique cut in distal third of proximal phalanx (open or skin flap technique both possible);
2. exarticulation through proximal interphalangeal joint;
3. exarticulation through distal interphalangeal joint.

3. exarticulation through distal interphalangeal joint

(technique both possible); 2. exarticulation through proximal interphalangeal joint;

1. amputation with oblique cut in distal third of proximal phalanx (open or skin flap

Figure 7.7 Sites for digital amputation or disarticulation.



## Alternative amputation techniques

### ❖ Exarticulation at proximal interphalangeal joint

#### **Advantages:**

- End result of surgery is hollow cavity ideal for pressure packing by bandage or swabs
- Avoids exposure of medullary cavity of proximal phalanx which could allegedly become focus of post-operative infection

#### **Disadvantages:**

- Lengthy procedure
- Difficult to locate joint level axially for incision to expose articulation
- Liability to break scalpel blades in this awkward site
- Preferable use of 'sage knife' (a curved solid two-edged instrument) and a small curette

### ❖ Amputation through coronary band

Involves subsequent removal of extensor process of distal phalanx, proximal part of middle phalanx and the distal sesamoid. This technique is laborious, but was developed to retain potential for growth of a weight-bearing horny wall after surgery. Surgery preferably in recumbent patient.

- Groove is made 1 cm distal to horn-skin margin of coronary band
- Obstetrical wire saw cut to remove claw, passing through distal interphalangeal joint
- Removal of extensor process of distal phalanx, transecting extensor tendon at insertion
- Removal of proximal part of middle phalanx and distal sesamoid
- Curettage of distal articular cartilage of proximal phalanx

- Sharp dissection of any septic or otherwise discoloured soft tissue, or radical curettage

❖ **Amputation of accessory digits ('dewclaws')**

**Indication**

Prophylactic surgery on medial accessory digits of hind limbs to prevent self-inflicted teat trauma. Ethical as well as scientific objections to technique in Europe, therefore forbidden in many countries including UK and Switzerland. Common routine procedure in many North American dairies.

**Technique**

- Remove at two to eight weeks old in recumbent calf
- Clean and disinfect area
- Local infiltration analgesia (2 ml 2% lignocaine plain)
- Push digit proximally to move away from joint space and major vessels
- Resect through skin margin and dewclaw base with large scissors or Barnes dehorner, remaining superficial and so avoiding deeper digital vasculature
- Suture any wounds with significant haemorrhage
- Apply topical antibacterial powder, dry swab and adhesive tape dressing for one week